



Feline paraneoplastic alopecia associated with metastasising intestinal carcinoma

Journal of Feline Medicine and Surgery

Open Reports

1–5

© The Author(s) 2015

Reprints and permissions:

sagepub.co.uk/journalsPermissions.nav

DOI: 10.1177/2055116915621582

jfmsopenreports.com



Lisa-Maria Grandt¹, Anja Roethig¹, Sabrina Schroeder², Kernt Koehler², Judith Langenstein³, Nina Thom¹ and Reto Neiger¹

Abstract

Case summary A 10-year-old male neutered British Shorthair cat was presented with a 6 month history of lethargy, weight loss and alopecia. Clinical examination revealed widespread alopecia of the ventral abdomen and hindlimbs. The skin in these areas was smooth and shiny and hairs could be easily epilated. Spontaneous pruritus was observed. Cytological examination of superficial impression smears showed a severe *Malassezia* species dermatitis and pyoderma. Ectoparasites could not be detected and no sign of dermatophytosis was visible in trichograms and Wood's lamp analysis. Abdominal ultrasound found a focally thickened wall of the large intestine and multiple nodules in the liver. Fine-needle aspirates from lymph nodes, liver and altered colonic wall were consistent with an undifferentiated malignant neoplasia. The cat was euthanased at the owners' request, owing to potential neoplasia with metastatic spread. At necropsy a metastasising carcinoma of the colonic wall was found, as well as a paraneoplastic alopecia.

Relevance and novel information Feline paraneoplastic alopecia has been reported in association with pancreatic carcinoma, bile duct carcinoma and hepatocellular carcinoma, as well as with neuroendocrine pancreatic carcinoma and hepatosplenic plasma cell tumour. This is the first reported case of feline paraneoplastic alopecia associated with a colon carcinoma.

Accepted: 16 November 2015

Introduction

Cats with neoplasia often show unspecific clinical signs of chronic disease such as anorexia and weight loss. Paraneoplastic alopecia is predominantly present on the ventral abdomen and hindlimbs. Characteristic for paraneoplastic alopecia is smooth and shiny skin, which is inelastic and thin, but not fragile,^{1–5} with adjacent hairs that can be easily epilated. Pruritus is uncommon, but pruritic secondary infections with *Malassezia* species have been reported.^{6–8} Histopathologically, the main findings are atrophy of hair follicles, telogenisation, miniaturisation of the hair bulb and orthokeratotic and parakeratotic hyperkeratosis. Feline paraneoplastic alopecia has been reported in association with pancreatic carcinoma, bile duct carcinoma and hepatocellular carcinoma, as well as with neuroendocrine pancreatic carcinoma and hepatosplenic plasma cell tumour.^{1–10} The majority of cats also had metastases scattered throughout the liver.^{1–4,6,7,9,10} In one cat with a pancreatic carcinoma,

complete excision of the tumour resulted in full regrowth of hair. Alopecia relapsed after a few months and, in this case, metastatic disease was detected in the liver.¹⁰ These findings confirmed the paraneoplastic origin of that certain type of alopecia but the exact pathomechanism is still unknown.

¹Clinic for Small Animal Internal Medicine, Justus-Liebig University of Giessen, Giessen, Germany

²Institute of Veterinary Pathology, Justus-Liebig University of Giessen, Giessen, Germany

³Clinical Pathology, Justus-Liebig University of Giessen, Giessen, Germany

Corresponding author:

Lisa-Maria Grandt, Justus-Liebig University of Giessen, Clinic for Small Animal Internal Medicine, Frankfurterstrasse 124, 35392 Giessen, Germany

Email: lisa.grandt@vetsuisse.unibe.ch



Case description

A 10-year-old male neutered British Shorthair cat was presented for chronic lethargy and anorexia, as well as acute polyuria/polydipsia and faecal incontinence. The cat's general condition had deteriorated over the previous 6 months, with notable weight loss. Progressive alopecia had also been noticed by the owners. The cat was housed individually and had free outdoor access. The cat was negative for feline leukaemia virus status and feline immunodeficiency virus. Previous unsuccessful therapy consisted of antimicrobials and corticosteroids of unknown type and dose.

At clinical examination the cat was thin (body condition score 2/9) and had a bilateral purulent ocular discharge. Alopecia extended symmetrically from the ventral abdomen to the medial thighs. The skin in the alopecic areas was erythematous, smooth and glistening (Figure 1). Crusts and brown exudate were found between the toes. Spontaneous pruritus was present. Microscopic evaluation of impression smears taken from the abdomen and digits revealed a high amount of cocci and *Malassezia* species yeast. Ectoparasites could not be detected in multiple superficial and deep skin scrapings. Trichograms and Wood's lamp examination were negative for dermatophytosis.

The cat was hospitalised and started on intravenous fluids. To treat pyoderma and *Malassezia* species dermatitis amoxicillin/clavulanic acid (20 mg/kg q12h IV, AmoxClav; Hexal AG) and itraconazol (5 mg/kg q24h PO, itrafungol; Elanco Animal Health) were administered.

Haematology and serum biochemistry showed only mild changes, which were considered clinically insignificant. Urinalysis showed a mildly increased urine protein to creatinine ratio (0.32) and an inactive sediment. During the abdominal ultrasound approximately 1.5 cm of the colonic wall appeared hypoechogenic and thickened with loss of normal layering. Additionally, there were signs of mild focal peritonitis. Multiple target lesions in the liver and enlarged and hypoechogenic abdominal lymph nodes were suggestive of tumour metastases. Fine-needle aspirates were taken from lymph nodes, liver and the altered colonic wall. All samples contained atypical cells of the same type with signs of malignancy, including anisocytosis, anisokaryosis, pleomorphism, light basophilic cytoplasm and few atypical mitotic figures (Figure 2). All samples were of high cellularity and contained spindle-shaped to polygonal cells located in small clusters or as singletons. The cells possessed eccentrically located round-to-oval nuclei with reticular chromatin pattern, 1–2 often prominent nucleoli and moderate amounts of a lightly basophilic cytoplasm with several fine intracytoplasmic vacuoles, as well as distinct cellular borders. The cytological picture was consistent with a malignant undifferentiated tumour; however, determination of the histogenesis was not possible. Owing to the poor prognosis the owners

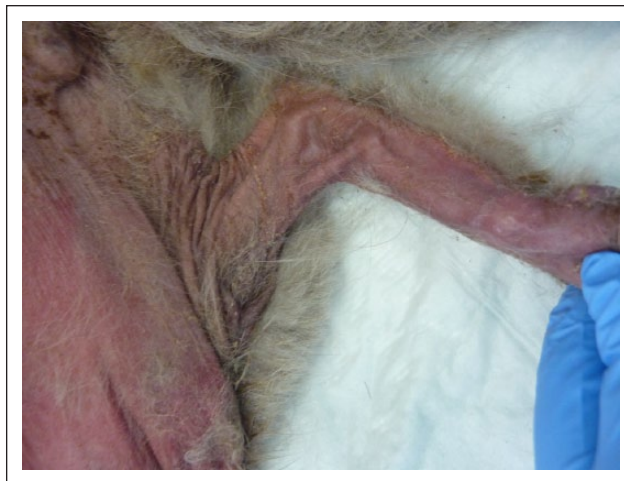

Figure 1 Widespread alopecia on the ventral abdomen and the hindlimbs. The skin is diffusely erythematous and smooth with small crusts

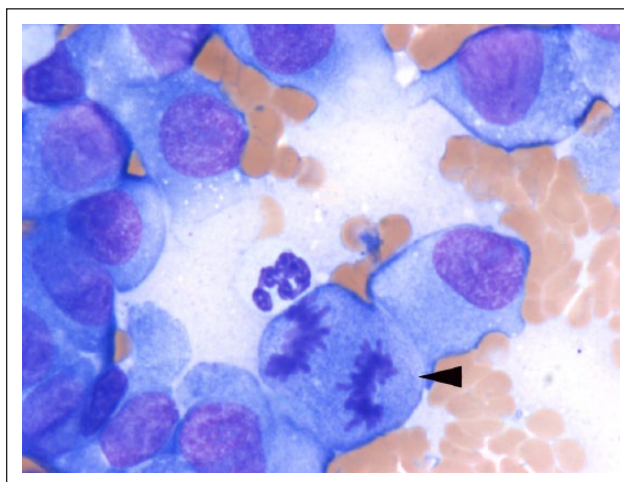


Figure 2 Cytology of abdominal lesions. Atypical neoplastic cells were detectable within fine-needle aspiration of lymph node, intestine and liver. Cells are increased in size with a high amount of basophilic cytoplasm, round-to-oval nuclei and prominent nucleoli. Numerous mitotic figures (arrowhead) were obvious. Papanheim stain ($\times 100$)

elect to have the cat euthanased. At necropsy the abdominal skin was diffusely alopecic and on the paws hyperaemic erosions were seen. A 2 cm \times 1 cm \times 0.3 cm ulcerated neoplasia of the dorsal colonic wall was found (Figure 3a). In this localisation there was a chronic peritonitis with fibrous adhesions involving the small intestine. On the serosal surface numerous dilated lymphatics and marked desmoplasia were noted. The omentum contained multiple disseminated firm white small nodules (Figure 3b). Similar nodules of 0.5–1.0 cm in diameter were found within the mesenteric lymph node, liver and diaphragm (Figure 3c).

Histopathology of the skin showed moderate hyperplasia and acanthosis, mild ortho- and parakeratotic

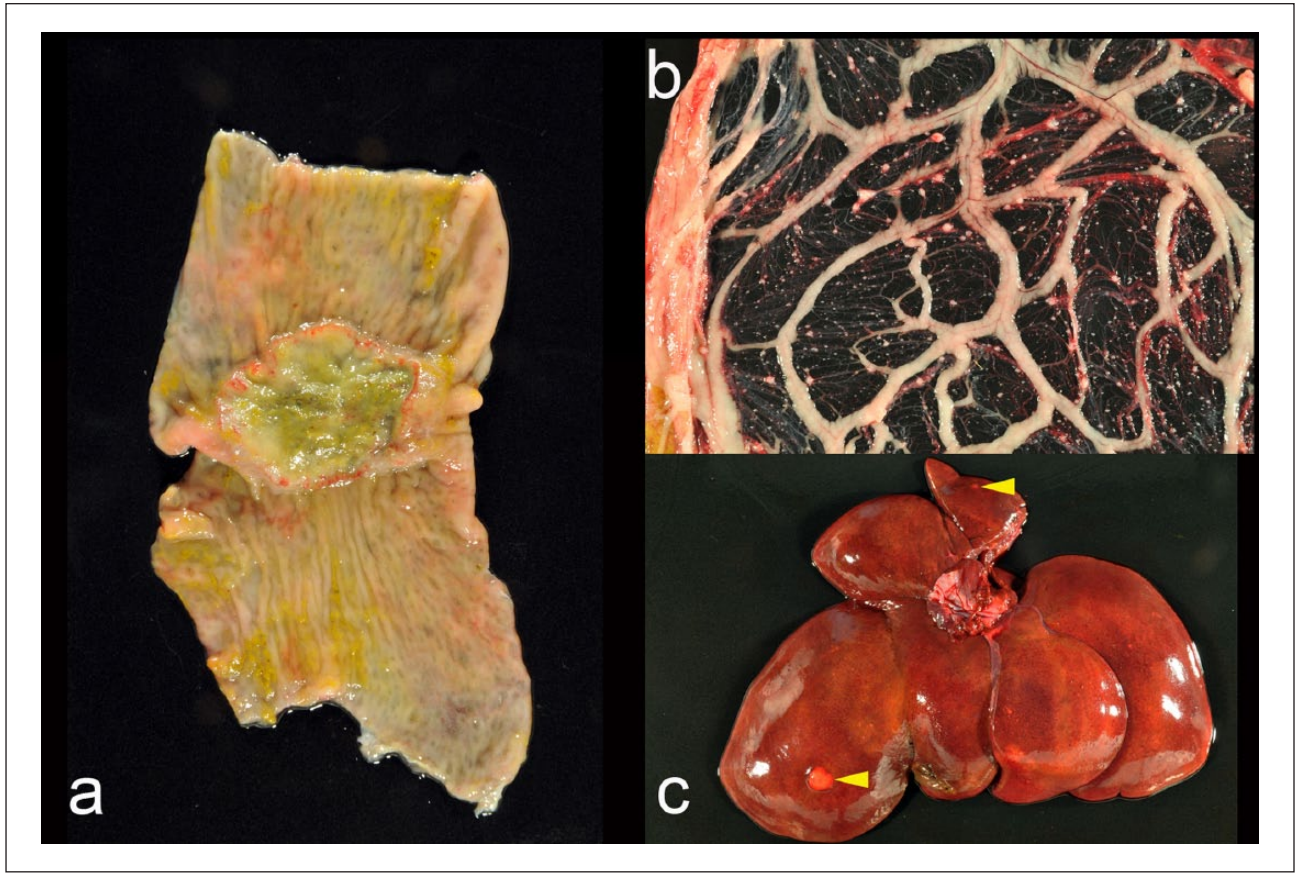


Figure 3 (a) Ulcerated exophytic neoplasia of the colonic wall. (b) Abundant transplantational metastases within the omentum. (c) Liver metastases (arrowheads)

hyperkeratosis with some yeasts between keratin layers and mild superficial pyoderma. Hair follicles were atrophic or predominantly in telogen phase of the hair cycle (Figure 4a, b). Sebaceous glands were unaltered. A few dilated infundibula filled with neutrophils and detritus (suppurative folliculitis) were detectable at the muzzles.

The intestinal neoplasia was identified as tubular-to-anaplastic carcinoma with desmoplasia and lymphatic invasion (Figure 5). Metastases were found within mesenteric lymph node, peritoneum and liver. Immunohistochemistry using pan-cytokeratin AE1/2 (PAP method) determined the epithelial origin of the neoplastic cells.

Discussion

Paraneoplastic alopecia in cats has been reported with carcinomas of the liver, bile duct and pancreas, as well as with neuroendocrine pancreatic carcinoma and hepatosplenic plasma cell tumour but so far not with intestinal carcinomas.¹⁻¹⁰

The differential diagnosis for feline-acquired alopecia includes infectious and non-infectious diseases. Dermatophytosis and *Demodex cati* infestation cause a primary alopecia, while other ectoparasites, such as

Cheyletiella blakei, *Notoedres cati*, *Demodex gatoi* or fleas, induce a pruritic dermatitis with secondary alopecia. Allergic disease, a primary pruritic disease, can lead to traumatic alopecia. Cutaneous infections with bacteria or yeast occur secondary to a primary skin disorder or systemic disease and can also result in pruritus and traumatic hair loss. Non-infectious diseases causing primary alopecia include immune-mediated lymphocytic mural folliculitis, pseudopelade and vasculitis. Dysfunctions of the hair growth cycle like telogen effluvium, hyperadrenocorticism or hypothyroidism occur very rarely in cats.

The striking dermatological finding of shiny skin, together with easily epilated hair and distribution of the affected areas lead to the suspicion of paraneoplastic alopecia in this cat. Paraneoplastic alopecia is a non-pruritic disease but secondary *Malassezia* species or bacterial infections can cause a significant pruritus. Cytological and histopathological findings confirmed pyoderma and yeast dermatitis in this cat. Although skin infections with yeast organisms in cats are reported with allergic disease,¹¹ it is more commonly reported in conjunction with severe internal diseases and also with paraneoplastic alopecia.⁶ In a retrospective study, 15/550 feline skin biopsies were positive for *Malassezia* species; 11/15 had severe internal disease and seven were highly suspicious for paraneoplastic

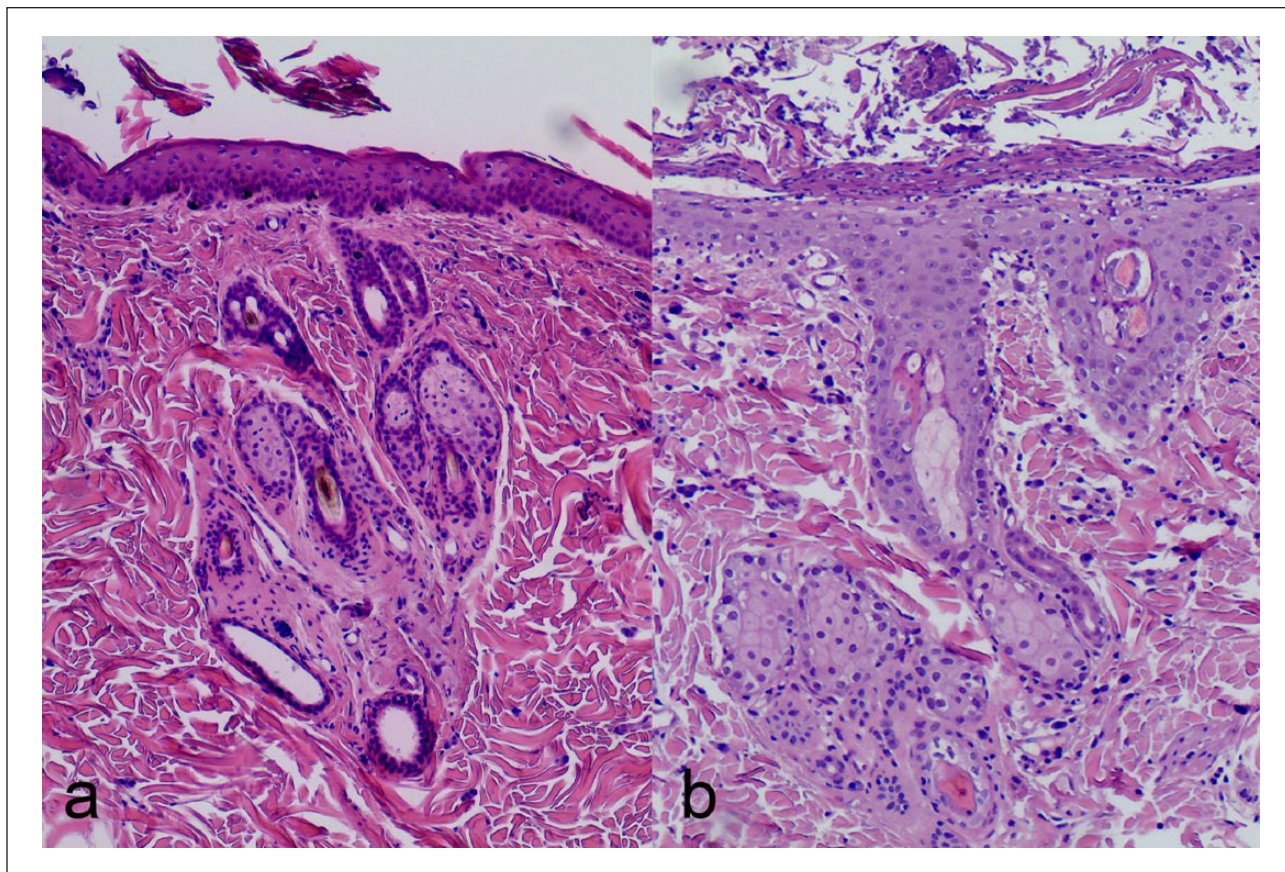


Figure 4 (a) Histopathology of the skin: moderate epidermal hyperplasia, atrophic, mostly telogen and kenogen hair follicles. (b) Area with parakeratosis, crusts and superficial dermatitis. Haematoxylin and eosin ($\times 20$)

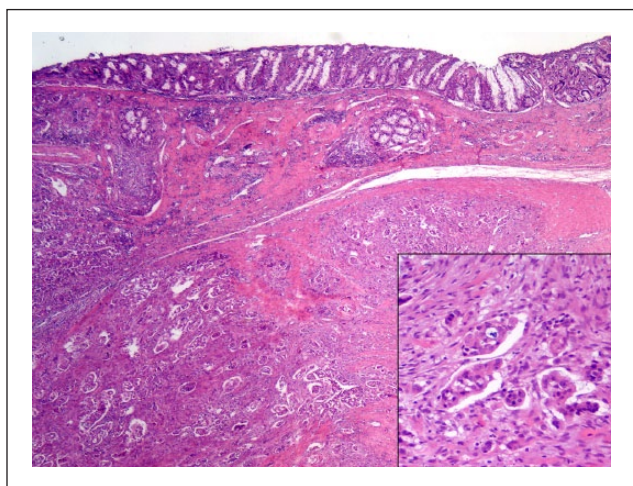


Figure 5 Colon: in the upper left corner ulceration of the mucosa and transmural infiltration with neoplastic cells and desmoplastic response. Haematoxylin and eosin ($\times 10$). Inset: nests of neoplastic cells within lymph vessels. Haematoxylin and eosin ($\times 40$)

alopecia.⁶ Following abdominal ultrasound the most likely clinical diagnosis was a paraneoplastic alopecia due to an intestinal tumour. Cytological examination of fine-needle

aspirates detected atypical cells with clear signs of malignancy. Owing to the poor prognosis, the owners requested euthanasia and no further ante-mortem tests such as adrenocorticotropic hormone-stimulation test were performed.

The histopathological findings confirmed a malignant tumour of the colon (tubular-to-anaplastic carcinoma) and the diagnosis of feline paraneoplastic alopecia. Adenocarcinoma is the second most common intestinal neoplasm in cats. The incidence varies between 0.4% and 29.0%, males suffer more often from intestinal carcinoma than queens and a breed predisposition in Siamese cats has been proposed. In a case series of 46 cats, 21 were diagnosed with adenocarcinoma. At time of diagnosis 16/21 already had metastatic spread into abdominal organs. Recommended treatment is a subtotal colectomy in combination with doxorubicin chemotherapy.¹² No mechanism explaining feline paraneoplastic alopecia has been proposed, as it is a rare entity and no comparable disease has been described in human medicine. Recently, a case of suspected paraneoplastic alopecia has been described in a woman suffering from cholangiocarcinoma and localised alopecia.¹³ With complete excision of the tumour, regrowth of hair was noticed, but alopecia reappeared simultaneously with occurrence of metastatic lesions. Owing to a lack of a dermatopathological examination, it is not clear

whether this disease truly resembles feline paraneoplastic alopecia. In contrast, a well-known cutaneous paraneoplastic syndrome in cats is thymoma-associated exfoliative dermatitis. The suspected pathomechanism of this disease is an activation of cytotoxic T lymphocytes targeting keratinocytes, initiated by the tumour.¹⁴ An underlying immunological process is not evident in feline paraneoplastic alopecia.

In most cases of feline paraneoplastic alopecia, affected cats already had liver metastases related to an abdominal carcinoma.^{2,4-7,10} Another paraneoplastic syndrome, more characterised in the dog, is superficial necrolytic dermatitis, or hepatocutaneous syndrome. Clinical signs consist of erythema, crusting, ulceration on footpads, mucocutaneous junctions and on pressure points.¹⁵ Underlying internal diseases are diabetes mellitus, vacuolar hepatopathy and neuroendocrine or pancreatic tumours. The presumed pathomechanisms are changes in metabolism such as hypoaminoacidaemia, hyperglucagonaemia and altered zinc levels. A high-quality protein diet and amino acid supplementation is helpful in some patients; this may underline the metabolic nature of the disease.¹⁶ In paraneoplastic alopecia metabolic changes have not been described thus far, but almost all cats had liver metastasis. It is conceivable that changes in the liver metabolism are contributing to the paraneoplastic alopecia more than the primary tumour. Further research is necessary to determine the underlying mechanism.

Conclusion

In cats with typical clinical signs such as shiny skin, easily epilated hairs and systemic disease abdominal malignancies have to be considered as a cause of non-pruritic alopecia.

Funding The authors received no financial support for the research, authorship, and/or publication of this article.

Conflict of interest The authors declared no potential conflicts of interest with respect to the research, authorship, and/or publication of this article.

References

- Pascal-Tenorio A, Olivry T, Gross TL, et al. **Paraneoplastic alopecia associated with internal malignancies in the cat.** *Vet Dermatol* 1997; 8: 47–52.
- Barrs VR, Martin P, France M, et al. **What is your diagnosis?** *J Small Anim Pract* 1999; 40: 595–596.
- Turek MM. **Invited review – cutaneous paraneoplastic syndromes in dogs and cats: a review of the literature.** *Vet Dermatol* 2003; 14: 279–296.
- Marconato L, Albanese F, Viacava P, et al. **Paraneoplastic alopecia associated with hepatocellular carcinoma in a cat.** *Vet Dermatol* 2007; 18: 267–271.
- Sharpe SJ, Meadows RL, Senter DA, et al. **Pathology in practice. Liver malignancy and paraneoplastic alopecia in a cat.** *J Am Vet Med Assoc* 2014; 244: 1265–1267.
- Godfrey DR. **A case of feline paraneoplastic alopecia with secondary *Malassezia*-associated dermatitis.** *J Small Anim Pract* 1998; 39: 394–396.
- Mauldin EA, Morris DO and Goldschmidt MH. **Retrospective study. The presence of *Malassezia* in feline skin biopsies. A clinicopathological study.** *Vet Dermatol* 2002; 13: 7–14.
- Caporali C, Binanti D, Albamese F, et al. **Two cases of feline paraneoplastic alopecia associated with a neuroendocrine pancreatic carcinoma and a hepatosplenic plasma cell tumour.** *Vet Dermatol* 2014; 25: 380–406.
- Brooks DG, Campbell KL, Dennis JS, et al. **Pancreatic paraneoplastic alopecia in three cats.** *J Am Anim Hosp Assoc* 1994; 30: 557–563.
- Tasker S, Griffon DJ, Nuttall TJ, et al. **Resolution of paraneoplastic alopecia following surgical removal of a pancreatic carcinoma in a cat.** *J Small Anim Pract* 1999; 40: 16–19.
- Ordeix L, Galeotti F, Scarampella F, et al. **Malassezia spp. overgrowth in allergic cats.** *Vet Dermatol* 2007; 18: 316–323.
- Slawinski MJ, Mauldin GE, Mauldin GN, et al. **Malignant colonic neoplasia in cats: 46 cases (1990–1996).** *J Am Vet Med Assoc* 1997; 211: 878–881.
- Antoniou EI, Paraskeva P, Smyrnis A, et al. **Alopecia: a common paraneoplastic manifestation of cholangiocarcinoma in humans and animals.** *BMJ Case Rep* 2012; 2012: DOI: 10.1136/bcr-2012-006217.
- Rottenberg S, von Tscharner C and Roosje PJ. **Thymoma-associated exfoliative dermatitis in cats.** *Vet Pathol* 2004; 41: 429–433.
- Miller WH, Jr, Griffin CE and Campbell KL. **Feline paraneoplastic alopecia.** In: Miller WH, Jr, Griffin CE and Campbell KL (eds). *Muller and Kirk's small animal dermatology*. 7th ed. ??: Saunders, 2013, 568–569.
- Byrne KP. **Metabolic epidermal necrosis-hepatocutaneous syndrome.** *Vet Clin North Am Small Anim Pract* 1999; 29: 1337–1355.