

**THE ROLE OF CAPILLAROSCOPY
IN RHEUMATOLOGY**

**Inauguraldissertation zur Erlangung
des Grades eines Doktors der Medizin
des Fachbereichs Medizin der Justus-
Liebig-Universität Gießen**

**vorgelegt von
Sevdalina Nikolova Lambova
aus Plovdiv, Bulgarien**

Gießen 2011

Aus dem Lehrstuhl für Innere Medizin mit
Schwerpunkt Rheumatologie der Justus-Liebig-
Universität Gießen

Ärztlicher Direktor: Prof. Dr. med. Ulf Müller-
Ladner

Gutachter: Prof. Dr. med. Ulf Müller-Ladner

Gutachter: Prof. Dr. med. Matthias Goebeler

Tag der Disputation: 16 December 2011

CONTENT

ABBREVIATIONS.....	7
CHAPTER I. REVIEW OF THE LITERATURE.....	9
1. Introduction.....	9
1. 1. History of capillaroscopy.....	9
1. 2. The cutaneous microcirculation.....	9
1. 3. Performing a capillaroscopic examination.....	11
1. 4. Equipment	11
2. Capillaroscopic parameters	13
3. Age-related changes in capillaroscopic parameters.....	19
4. Key capillaroscopic parameters.....	20
5. Additional possibilities of nailfold videocapillaroscopy and other techniques for evaluation of microcirculation.....	21
6. Indication for performing capillaroscopy in rheumatologic practice.....	22
7. Capillaroscopic pattern in rheumatic diseases.....	23
7. 1. Secondary Raynaud's phenomenon.....	23
7. 1. 1. Systemic sclerosis.....	24

7. 1. 1. 1. Capillaroscopic pattern in the hands of systemic sclerosis patients.....	24
7. 1. 1. 2. Capillaroscopic pattern and digital ulcers in systemic sclerosis.....	31
7. 1. 1. 3. Foot involvement in systemic sclerosis.....	31
7. 1. 2. Systemic lupus erythematosus.....	33
7. 1. 3. Undifferentiated connective tissue disease.....	36
7. 1. 4. Inflammatory arthritis.....	37
7. 1. 4. 1. Rheumatoid arthritis.....	37
7. 1. 4. 2. Psoriatic arthritis	38
7. 1. 4. 3. Early arthritis.....	39
7. 1. 5. Other rheumatic diseases.....	40
7. 1. 5. 1. Primary Raynaud’s phenomenon.....	40
7. 1. 5. 2. Primary fibromyalgia.....	43
7. 1. 5. 3. Paraneoplastic Raynaud’s phenomenon.....	44
8. Capillaroscopic changes in arterial hypertension.....	45
9. Analysis of the capillaroscopic images	47
10. State of the art and actuality of the subject.....	48

CHAPTER II. AIM AND TASKS OF THE DISSERTATION.....52

1. The objective of the dissertation.....	52
---	----

2. Tasks.....	52
---------------	----

CHAPTER III. MATERIALS AND METHODS.

INCLUSION AND EXCLUSION CRITERIA.....	54
1. Patients.....	54
2. Technical equipment.....	57
3. Immunologic tests.....	59
4. Other methods	59
5. Statistical methods.....	61
6. Inclusion and exclusion criteria.....	62
6. 1. Inclusion criteria.....	62
6. 2. Exclusion criteria.....	65

CHAPTER IV. RESULTS.....

1. Systemic sclerosis.....	66
1. 1. Capillaroscopic pattern of the hands of systemic sclerosis patients.....	66
1.2. Association between capillaroscopic pattern and presence of digital ulcers in systemic sclerosis.....	70
1. 3. Capillaroscopic pattern of the toes in systemic sclerosis patients.....	71
2. Capillaroscopic pattern in systemic lupus	

erythematosus.....	78
3. Capillaroscopic pattern in undifferentiated connective tissue disease.....	85
4. Capillaroscopic pattern in inflammatory arthritis.....	87
4. 1. Capillaroscopic pattern in rheumatoid arthritis.....	87
4. 2. Capillaroscopic pattern in psoriatic arthritis.....	91
4. 3. Capillaroscopic pattern in early arthritis.....	93
5. Capillaroscopic pattern in other rheumatic diseases..	94
5. 1. Capillaroscopic pattern in primary Raynaud’s phenomenon.....	94
5. 2. Capillaroscopic pattern in primary fibromyalgia...	95
5. 3. Capillaroscopic pattern in paraneoplastic Raynaud’s phenomenon.....	98
6. Capillaroscopic pattern in arterial hypertension.....	103
7. Comparison of qualitative and quantitative analysis of capillaroscopic images in patients with rheumatic diseases and evaluation the reproducibility of the qualitative assessment performed by two different investigators.....	105
CHAPTER V. DISCUSSION.....	119

1. Systemic sclerosis.....	119
1. 1. Capillaroscopic pattern of the hands of systemic sclerosis patients.....	119
1.2. Association between capillaroscopic pattern and presence of digital ulcers in systemic sclerosis.....	121
1. 3. Capillaroscopic pattern of the toes in systemic sclerosis patients.....	122
2. Capillaroscopic pattern in systemic lupus erythematosus.....	126
3. Capillaroscopic pattern in undifferentiated connective tissue disease.....	127
4. Capillaroscopic pattern in inflammatory arthritis.....	128
4. 1. Capillaroscopic pattern in rheumatoid arthritis...	128
4. 2. Capillaroscopic pattern in psoriatic arthritis.....	130
4. 3. Capillaroscopic pattern in early arthritis.....	131
5. Capillaroscopic pattern in other rheumatic diseases.....	134
5. 1. Capillaroscopic pattern in primary Raynaud’s phenomenon.....	134
5. 2. Capillaroscopic pattern in primary	

fibromyalgia.....	138
5. 3. Capillaroscopic pattern in paraneoplastic Raynaud’s phenomenon.....	139
6. Capillaroscopic pattern in arterial hypertension.....	140
7. Comparison of qualitative and quantitative analysis of capillaroscopic images in patients with rheumatic diseases and evaluation the reproducibility of the qualitative assessment performed by two different investigators.....	141
8. Conclusions and original contributions.....	143
CHAPTER VI. SUMMARY.....	149
ZUSAMMENFASSUNG.....	153
CHAPTERVII. REFERENCES:.....	157
Acknowledgements.....	183
List of publications and scientific abstracts.....	185
Erklärung.....	192
Curriculum vitae.....	193

ABBREVIATIONS

ACA	Anticentromere antibodies
ACE	Angiotensin converting enzyme
ARA/ACR	American Rheumatism Association/American College of Rheumatology
AH	Arterial hypertension
ANA	Antinuclear antibodies
CCP	Cyclic citrullinated peptide
CRP	C-reactive protein
CTD	Connective tissue disease
DM	Dermatomyositis
ESR	Erythrocyte sedimentation rate
EULAR	European League Against Rheumatism
mm	Millimetre
µm	Micrometre
PM	Polymyositis

PsA	Psoriatic arthritis
RA	Rheumatoid arthritis
RF	Rheumatoid factor
RP	Raynaud's phenomenon
SD	Standard deviation
SLE	Systemic lupus erythematosus
SSc	Systemic sclerosis
UCTD	Undifferentiated connective tissue disease

CHAPTER I

REVIEW OF THE LITERATURE

1. Introduction

1. 1. History of capillaroscopy

Nailfold capillaroscopy is an imaging technique, which is used in medicine since 1823. In this year, Purkinje described skin capillaries when observing the nail-bed with a magnifying glass [99]. In 1911, Lombard has found that capillaries of the nailfold become visible for examination by microscope after placing a drop of immersion oil. 30 years ago, Maricq and Le Roy describe the specific capillaroscopic pattern in SSc. Since then the nailfold capillaroscopy has been found to be a non-invasive, inexpensive, easy to repeat imaging technique, which is of considerable importance for the evaluation of microcirculation in vivo [19,33,34,35,37,38,89, 90,92,123,126].

1. 2. The cutaneous microcirculation

Cutaneous microcirculation consists of two horizontally-oriented plexuses. The blood vessels of the underlying skeletal muscles and the subcutaneous fat

tissue form the deeply located plexus, which is located at the border between the skin and the subcutaneous layer. Ascendent arterioles and descendent venules connect the deep and the superficial plexus. The superficial plexus is located 1-1.5 mm under the skin surface. The capillary loops of the dermal papillae, which represent the nutritional part of the microcirculation, origin from the superficial plexus. 1 to 3 capillary loops are located in each dermal papilla. In most areas of the finger, capillaries in dermal papillae are located in a 90° angle to the skin surface, so only the tip of the capillary loops can be seen with the form of a dot or a comma. These are the nutritional capillaries, which represent 15% of the cutaneous microcirculation. The rest 85% are used for thermoregulation. The function of the nutritional capillaries is to supply diffusion of oxygen and nutrients from the capillaries to the tissues. In the nailfold area, the capillary loops become more parallel to the skin surface, and in the last row they can be observed in their full length. The capillaries consist of an arterial and a venous part, and an apical loop, which connects these two. The arterial limb is narrower than the venous and the ratio of

the venous-to-arterial diameter is approximately 1.2 - 1.5:1 [19,21].

1. 3. Performing a capillaroscopic examination

For visualization of the capillaries, a drop of cedar oil has to be placed on the nailfold. The patient is sitting with the hand at the heart level after a 15-20 minutes stay in a room with normal temperature of about 20-22°C [14,19,34,35,36,37,38]. The nailfolds of all ten fingers should be examined. However, the most precise morphologic evaluation is obtained at the fourth and fifth finger of both hands because of the highest transparency of the skin in these areas [34]. The following parameters are routinely evaluated: distribution, capillary shape, width, presence of dilated, giant capillaries, haemorrhages, avascular areas, neoangiogenic capillaries [14,19,37,38,44,69,78, 89,90,91,113]. To consider capillaroscopic findings as abnormal, changes have to be observed at least in two fingers [34].

1. 4. Equipment

At the beginning, the nailfold capillaries are

examined with a light stereomicroscope that provides a magnification from 10x to 100x. For global evaluation of the vessels in the entire nailfold area, widefield capillaroscopy is used [19]. Other optical systems for visualization of capillaries (ophthalmoscopes, dermatoscopes) provide images with smaller magnification and lower quality, but they are useful, because they are a good alternative to perform capillaroscopic examinations in cases that require bedside examination [3,12,14,130]. However, digital videocapillaroscopy nowadays is a gold standard and consists of the combination of a microscope and a digital videocamera. It provides a significantly higher magnification from 50x to 1000x and it allows capillaroscopic parameters to be measured precisely. Several capillaroscopic parameters - width, length and capillary density may be measured quantitatively by special software programs [3,37,38,62], while others such as presence of haemorrhages, which are important markers for microangiopathy may be assessed qualitatively or semiquantitatively.

2. Capillaroscopic parameters

Using different capillaroscopic devices, the following capillaroscopic parameters can be examined: capillary diameter (width), capillary length, shape, distribution, mean capillary density, presence of avascular areas, haemorrhages, neoangiogenic capillaries [14,19,22,37,38,44,69,78,81,89,90,91,113]. Some of these parameters such as capillary width, length, mean capillary density can be exactly measured and precise quantitative examination can be performed by the current available software programs, while other parameters, e.g. shape, distribution and haemorrhages are evaluated qualitatively. Counting the number of the haemorrhages, ramified capillaries per mm and evaluation of the degree of the derangement are methods for semiquantitative analysis of the capillaroscopic image.

a/ Capillary width

For this capillaroscopic parameter different and contradictory values are reported in the literature. Some authors measure the width of the arterial and the venous capillary limb and the apical capillary loop, while others report values about the whole width of the capillary loop

[19,44,60,78,81,88,91,113]. The diameter of the arterial and the venous limb have to be measured in their widest part, the apical loop - in its central part, the whole width of the capillary loop - in its widest part. In fact, only the column of the red blood cells can be measured while the capillary wall is not visible. The reported values for the capillary width of the nutritive capillaries of the nailfold of the fingers vary between 6 and 15 μm for the arterial limb, and between 8 and 20 μm for the venous limb. Experimental studies have demonstrated that the real diameter is actually wider than those, which can be measured with 3.5-4.9 μm for the arterial limb and with 3.8-5.4 μm for the venous limb. Mean capillary width is the mean value of the three widest capillary loops [44,69]. The upper normal limit for the whole width of the capillary loop is reported to be between 25 and 50 μm [35,59,65]. Maricq et al. have defined as giant capillaries those vessels that exceed the upper limit of the width of normal vessels 4 to 10 times [44,69,81]. The majority of authors classify as dilated capillaries, whose arterial diameter is wider than 15 μm or the venous limb is wider than 20 μm . And as giant capillary loops define

microvessels with diameter of either an arterial or a venous limb greater than $50\mu\text{m}$ [19,44,69,78,91,119].

b/ Capillary length

This is the distance between the bend of the capillary loop to its base, but it is sometimes difficult to define the second mark, because it depends on the skin transparency and this parameter inherits subjective variations [62]. Kabasakal et al. found mean values for this parameter in healthy adults of $250\ \mu\text{m}$ and the upper normal limit of $300\ \mu\text{m}$ [69]. Mean values, reported by Lefford, for this parameter in healthy individuals are lower - $146\ \mu\text{m}$ [81].

c/ Distribution

The normal distribution of the capillaries in the nailfold is regular and parallel [19]. Considering this, the degree of disarrangement is evaluated.

d/ Shape

The capillary loops in the most areas of the human body are perpendicular to the skin surface, while at the nailfold they become parallel to the skin surface. This allows to be visualized with their whole length. The normal shape of the capillaries of the nailfold is like

hairpin or the Latin letter U [19,119].

e/ Mean capillary density

This parameter reflects the number of capillaries per mm. Age-related changes of this parameter have to be considered. Most authors have found a tendency of an increase in mean capillary density during maturation. Aging is associated with a tendency of reduction of mean capillary density. Dolezalova et al. (2003) have found an increase of mean capillary density in healthy children. In 17 healthy children and 20 healthy adults, the mean capillary density was 6.7 capillaries/mm in children and 8.9 capillaries/mm in adults respectively [44]. Similar are the findings of the British authors (Herrick et al., 2000), who found a mean capillary density in 110 healthy children at the age between 6-15 years – 5 – 7.3 capillaries/mm. The authors have found an increasing tendency for the arterial and the venous diameter with growing, without change in the values of the apical loop and mean capillary density [60]. Cony et al. (1992) found a mean capillary density in healthy children – 9 capillaries/mm and in adults - 10 capillaries/mm [31]. Different are the measured values for this parameter of

Italian authors (Martino et al., 1997) – 9 capillaries/mm in healthy children and 14 capillaries/mm in adults [93]. A large study has been conducted by Terreri et al. (1999), that includes 329 children at the age between 2.1 and 16.7 years. The mean capillary density in this group was 6.8-7.3 capillaries/mm. An increase in mean capillary density has also been observed during growing and only in the age group above 10 years the authors have found values for this parameter similar to those in adults [140].

f/ Avascular areas

The avascular area is defined as a distance between two adjacent capillary loops from the distal rows greater than 500 μm or above 300 μm in the proximal area [119]. Avascular areas may be single or confluent [19]. For evaluation of the degree of capillary loss Lee et al. (1983) have proposed a 4 - stage scale: stage 0 - no avascular areas; stage 1 – mild capillary loss, that includes up to 2 avascular areas; stage 2 – moderate capillary loss with more than 2 avascular areas, stage 3 - severe loss of capillaries - frequent and confluent avascular areas [78]. Avascular areas often are surrounded by capillaries with disturbed distribution,

oriented towards the area of capillary loss [19].

g/ Presence of haemorrhages, thrombosis and extravasates

Haemorrhages appear as extracapillary brown aggregations of erythrocytes with variable form and have to be differentiated from extravasates and thrombosis. The appearance of haemorrhages is an indicator of early vascular damage [19].

h/ Neoangiogenesis

It is a presence of newly formed vessels. Meandering capillaries, presence of more than one capillary loop in a single dermal papilla, ramified and bushy capillaries are the morphological substrate of neoangiogenesis [19,38,89,113].

i/ Visibility of the subpapillary plexus

Usually it is not visible, although in 30% of healthy individuals it may occur. The blood flow in the subpapillary plexus is slower in comparison with the capillary loops. When the blood flow is abnormally slowed up, the subpapillary plexus is always visible and even prominent. In these cases of delayed blood flow, the finding is described as “dilated and prominent

subpapillary plexus”. The dilation of the venous (efferent) limb of the capillary loop and/or prominent subpapillary plexus provide both an evidence for a delayed blood flow [19].

j/ Other findings

The presence of capillaries with crossed arterial and venous limbs (criss-cross forms, figure of eight) is a normal variant. This finding can be observed depending on the different angles of observation. Tortuous capillaries are also a normal variant, but only when they are less than 5% of all capillaries. “Increased tortuosity” is defined as presence of more than 10% tortuous capillaries of all capillaries [110].

3. Age-related changes in capillaroscopic parameters

As mentioned above the process of growing is related to an increase of mean capillary density, which is a part of maturation [44,140], while during aging a decrease of capillary density has been observed [72,126]. Li Li et al. (2006) examined 50 healthy women by videocapillaroscopy and laser Doppler and found a

tendency of reduction of capillary count during aging as well as an increase of intercapillary distance, capillary length, and visibility of the subpapillary plexus. In addition, an increased blood flow has been observed via capillaroscopy, which is explained with the process of age-related skin changes in the epidermis, which becomes thinner and more transparent. The reduced size and count of capillary loops is probably related to the age-related changes in metabolism, reduced oxygen supply, tissue hypoxia and is a part of the aging process. The increased capillary length may be related to the process of angiogenesis and the subpapillary plexus may possess a potential for remodeling [82,83,96]. Ingegnoli et al. (2005) examined 123 SLE patients and did not find a significant change in the values of capillaroscopic parameters in different age groups [67].

4. Key capillaroscopic parameters

The key capillaroscopic parameters, which are indicators for microangiopathy, are giant capillaries, haemorrhages, avascular areas and neoangiogenic capillaries. The appearance of giant capillaries and

haemorrhages are parameters with a high positive predictive value for the development of CTD. The presence of tortuous capillaries is a variety of the normal. The elongation of capillary loop is not a sure marker for microangiopathy and short capillaries may be found in the cases with reduced transparency of the skin [19,33,34,35,37,38,42,69].

5. Additional possibilities of nailfold videocapillaroscopy and other techniques for evaluation of microcirculation

Besides native, fluorescent videocapillaroscopy also exists and is appropriate for detection of minimal microvascular abnormalities. In healthy subjects, there is a thin perivascular halo, while in SSc with secondary RP, there is an irregularly increased capillary permeability [19,126].

Nailfold capillaroscopy, laser Doppler and power Doppler are methods for an evaluation of the microcirculation. Measurement of the systolic pressure of the digits and colour Doppler provides information for larger blood vessels – the digital arteries. Thermography

and plethysmography provide information for both microvessels and digital arteries. However, the nailfold capillaroscopy is the only method for evaluation of nutritional capillaries of the nailfold area [57,61,147].

6. Indication for performing capillaroscopy in rheumatologic practice

The main indication for the capillaroscopic examination in rheumatology are the patients with RP, who are a common diagnostic problem in the rheumatologic practice. RP is caused by a reversible vasospasm of the small arteries and arterioles of the fingers and toes provoked by cold temperatures and emotional stress. It may affect also the nose, the tongue and other acral parts of the body. It manifests usually in three phases: ischemia, asphyxia and reactive hyperemia with skin discolouration from pallor to cyanosis and erythema. RP can be primary and secondary [11,17,19,34,36,38,63,64]. Secondary RP is a common sequela in a number of rheumatic diseases and nailfold capillaroscopy plays a key role in differentiation of primary and secondary forms of RP together with the

specific immunologic tests [14,31,33,34,35,36, 37,38,48,50,52]. Current knowledge about this technique shows a characteristic pattern in secondary RP in the context of SSc and scleroderma-spectrum disorders. Its potential use has been studied also in other rheumatic disease e. g., SLE, Sjögren syndrome, antiphospholipid syndrome, RA etc. [1,9,17,19,20,24,40,47,52,53,56, 67,69,70,101,102,113,115,133,139,142] as well as in non-rheumatic diseases e. g., AH, diabetes mellitus etc. [5,6,7,28,48,105,112]. At present, capillaroscopy is still insufficiently applied in rheumatologic practice, rather by dermatologists or angiologists, thus prolonging the diagnostic process and increasing its cost. In addition, the lack of guidelines for performing capillaroscopy, the ill-defined normal range of the capillaroscopic parameters, and the imprecise interpretation of the capillaroscopic patterns are the limiting factors for a widespread use in daily rheumatologic practice [55].

7. Capillaroscopic pattern in rheumatic diseases

7. 1. Secondary RP

Older age of onset, clinical features for autoimmune disease, trophic alterations of the fingers, positive autoantibodies and abnormal capillaroscopic findings are the characteristic features of secondary RP in rheumatic diseases [33,84,122,132].

7. 1. 1. Systemic sclerosis

7. 1. 1. 1. Capillaroscopic pattern in the hands of systemic sclerosis patients

RP is one of the most common symptoms in SSc with a frequency of approximately 90-95% and is usually the initial symptom, that precedes other features of the disease by years [17,87,122]. RP in SSc is severe and often presents with digital ulcers. The female to male ratio is 4:1 [122]. The capillaroscopic pattern in SSc is specific and is characterized by presence of dilated and giant capillaries, haemorrhages, avascular areas and neoangiogenic capillaries. It has been described for the first time by Maricq et al. (1980) and is called “scleroderma” type capillaroscopic pattern [12,19,34,35,36,37,38,39,89,90,91,92,124]. This specific capillaroscopic pattern is found in a great number of

cases with overt scleroderma (83-93%, Maricq) [37,90]. Bergman and co-workers found this type of specific capillaroscopic changes in 70.4% (19/27) of examined SSc patients [14], Nagy et al. in 87.5% of patients with diffuse SSc and in 61.6% of cases with limited form of the disease among 102 examined SSc patients [101]. Maricq et al. (1983) described two types of capillaroscopic changes in SSc – the “active” and “slow” pattern. Extensive and confluent avascular areas and neovascularization is supposed to reflect activity and progression of the disease (so-called “active” capillaroscopic pattern). In contrast, the presence of giant capillary loops with minimal loss of capillaries is typical for the forms of the disease with a lower activity (so-called “slow” capillaroscopic pattern) [19,90,127]. Maricq et al. found that some of the parameters of this pattern can also be observed in a group of disease from scleroderma spectrum disorders e. g. mixed connective tissue disease, UCTD, overlap syndromes, DM and have defined these findings as “scleroderma-like” capillaroscopic pattern [19,34,37,38,41,49,89, 91,101,128,137].

Cutolo (2000) described three phases of capillaroscopic changes in SSc:

i/ an “early” phase- appearance of few dilated and/or giant capillaries and few haemorrhages. In this phase, the distribution is relatively preserved without loss of capillaries. These findings are of crucial importance for the early diagnosis of SSc.

ii/ an “active” phase – there are high numbers of giant capillaries and haemorrhages. In addition, a moderate loss of capillaries, slight derangement and diffuse pericapillary oedema can be found.

iii/ a “late” phase – it is characterized by severe loss of capillaries with extensive avascular areas, bushy and ramified capillaries, more than one capillary loop in a dermal papilla, which are the morphological substrate of the defective neoangiogenesis [35].

The authenticity of the capillaroscopic changes in SSc has been confirmed histologically [127].

The capillaroscopic changes in SSc in the course of the disease is being explained by the action of different factors on angiogenesis. In the early stages of the disease, a pro-inflammatory state and an increased

production of vascular endothelial growth factor stimulate angiogenesis. As a result, capillaroscopic analysis of the nailfold bed demonstrates the presence of microhemorrhages and giant capillary loops. The short pro-angiogenic response is followed by a dramatic impairment of the angiogenic process. This switch is being explained by the action of antiangiogenic factors, which are thought to be markers for degradation of the extracellular matrix and other circulating proteins: angiostatin (a product of plasminogen cleavage), endostatin (of collagen XVIII), tumstatin (of collagen IV) and canstatin (of A2, IV collagen). Local tissue hypoxia and increased level of hypoxia induced factor also contribute to the defective neoangiogenesis. As a result, in the following stages capillaroscopic examination reveals a reduced capillary density, followed by extensive avascular areas, areas of desertification, severe architectural derangement, neoangiogenic capillaries, which are a proof of an abortive vascular recovery [98,121,125].

A relationship between capillaroscopic changes and the type of SSc, its activity and the visceral organ

involvement has been proposed [19,25,26,35,36,39, 73,90, 108,118], but not all authors do agree to this idea [78,86,141]. Severe capillary loss was noticed to be more common in patients with diffuse SSc. While dilated capillaries without loss of capillaries were found more frequently in patients with limited SSc - in 42% versus 10.9% in patients with diffuse form of the disease among the examined 105 SSc patients (50 with limited SSc and 55 with diffuse form) [108].

Cutolo et al. (2004) found in 241 SSc patients, that the presence of anti-topoisomerase antibodies (anti - Scl-70) correlates with “active” and “late” capillaroscopic changes and probably accelerate the appearance of these findings. Positive ACA were observed to be more common in patients with an “early” phase capillaroscopic pattern and probably delay the development of “late” capillaroscopic changes [36]. Bredemeier and co-authors (2004) in 91 SSc patients ascertained a relationship between loss of capillaries in the nailfold beds, skin involvement and activity of pulmonary disease as evaluated by high-resolution computed tomography [22]. It has been suggested that

the dynamics of the alterations of the capillaroscopic pattern during the follow-up of patients with CTD could also be an indicator for visceral vascular involvement in the future [39,95,123].

At present, for the diagnosis of SSc the ARA/ACR criteria (1980) are used [94]. Nagy et al. found in 447 patients with CTD a high specificity of capillaroscopy for early diagnosis of SSc. An abnormal “scleroderma” type capillaroscopic pattern was found in patients who did not fulfil the ACR criteria. These patients presented with sclerodactyly, teleangiectasia, subcutaneous calcinosis, oesophageal dysmotility and other symptoms [101]. In 2001, Lonzetti et al. published a letter, in which the authors evaluated the sensitivity of the ACR classification criteria for SSc in a group of 259 scleroderma patients. Using a regression tree analysis, they found that in limited SSc inclusion of the abnormal capillaroscopic pattern as a criterion would improve the sensitivity of the ACR criteria from 33.6 to 82.9%. Adding of clinically visible capillary telangiectasias, increased the sensitivity to 88.8%, and the presence of ACA increased it further to 91.5% [80,85,143]. Hudson

et al. (2007) also confirmed that inclusion of the specific capillaroscopic changes as a criterion improves sensitivity of ACR criteria for SSc [66]. The ACR classification criteria for SSc are specific rather than sensitive and by using these criteria, an incorrect diagnosis is unlikely. Of note, they have been proposed prior to the discovery of the specific for SSc capillaroscopic changes and autoantibodies. After 2000, three proposals for classification criteria of SSc have been published. The specific capillaroscopic pattern has been included in two of them – the criteria of Le Roy and Medsger (2001) and the other presented by Maricq and Valter (2004). Le Roy and Medsger (2001) and Nadashkevich et al. (2004) proposed also the inclusion of presence of RP as a diagnostic criterion for SSc [80,92,100,143]. The high prevalence of microvascular abnormalities in SSc underlines the potential of RP and capillaroscopic changes for early diagnosis of the disease. To improve the early diagnosis of SSc, Le Roy and Medsger proposed patients with RP and abnormal nailfold capillaroscopic changes or positive specific for SSc autoantibodies to be diagnosed as “prescleroderma”

or limited SSc even in the absence of other manifestation of the disease [80].

7. 1. 1. 2. Capillaroscopic pattern and digital ulcers in systemic sclerosis

Digital ulcers are common complication in SSc patients. Capillaroscopic findings for prediction of their development are not defined. Alivernini et al. (2009) speculated about a possible association between the development of ulcerations and the presence of avascular areas at the capillaroscopic examination [2]. Sebastiani et al. (2009) found a correlation between capillaroscopic changes and the development of digital ulcers in 120 SSc patients. A significant association between presence of digital ulcers and the lower number of capillaries in the distal row, as well as with higher number of megacapillaries and higher loop diameter was observed. A capillaroscopic index for prediction development of digital ulcers in SSc patients has been proposed [120].

7. 1. 1. 3. Foot involvement in systemic sclerosis

La Montagna et al. (2002) examined the

involvement of the feet in 100 SSc patients and monitored these patients between 1 and 28 years (median range 7 years). Among the 100 SSc patients included in the study, 90% presented with features of RP of the feet versus 100% with RP of the hands. In 43% of the cases from this group, RP of the feet was presented at initial evaluation, while 47% developed it in the course of the follow-up. RP of the hands was registered in 100% of patients at the initial evaluation. The onset of clinically evident involvement of the feet was noted to occur later in limited SSc than in the diffuse form of the disease. Lower rates of necrotizing RP, tendon friction rubs and skin thickening scores were found in the feet of patients with SSc as compared with the hands, whereas arthralgias affected significantly more often the feet. Acroosteolysis, calcinosis and erosions were observed significantly more often in the hands of SSc patients. The authors concluded, that the involvement of the feet in SSc appears to be less frequent and with later onset, but can be similarly disabling [76].

In contrast to the now widely used microscopic examination of the nailfolds of the fingers, at present this

technique is not established for feet examination in the everyday rheumatologic clinical practice.

In 84 healthy subjects, Noy Delcourt et al. (1986) observed that the majority of the feet parameters are similar to those of the hands e. g., shape and capillary width. For other parameters the authors found some differences, such as a smaller number of capillary loops per mm, greater number of minor dystrophic forms, shorter capillary loops at the feet as compared with hands. In addition, in the feet of the examined healthy individuals, the more frequent findings as compared with hands were the irregularity in the distribution of the capillary loops and a peri-capillary haziness, which is associated with the physiological oedema of the feet. No major dystrophy was seen and traumatic hemorrhages were also not more frequent in the toes than in the fingers [106].

7. 1. 2. Systemic lupus erythematosus

The prevalence of RP in SLE is reported to be ranging from 10 to 45% and it usually indicates a more benign course without tissue necrosis [17,74].

Capillaroscopic pattern in SLE is less specific in comparison to SSc and the other above mentioned diseases, in which “scleroderma-like” capillaroscopic pattern may be presented [19,40]. Nailfold capillaroscopic changes in SLE include a wide range. According to some investigators, the majority capillaroscopic findings are non-specific [81]. The most frequent described specific changes in SLE are tortuous, meandering capillaries and bizarre-formed loops [113], an increased length of capillaries [52,69], an increased diameter [113] and a prominent subpapillary plexus [52,69]. In a part of the studies, these changes specific for SLE have been termed “SLE” type capillaroscopic pattern. Increased tortuosity can be found in 42% of SLE patients, but in only 6% of SSc patients [14,52,113].

The “scleroderma-like” capillaroscopic picture with dilated, giant capillaries, haemorrhages and avascular areas is a rare finding in SLE in contrast to other CTD. The frequency of the latter pattern is low, ranging from 2% to 9% [14,69,90,101] and slightly higher, reported by Furtado - 15% [47]. A number of investigators have found a correlation between

“scleroderma-like” capillaroscopic pattern and the presence of RP and anti-U1-RNP antibody. This finding is being explained with a potential subclinical overlap with SSc [47,56,67,81,89].

Data addressing the association between abnormal capillaroscopic findings and positive anticardiolipin antibodies are contradictory. It has been found a lack of correlation [67], a negative correlation [47], and a positive association [20,115]. The following mechanism could be proposed for the pathogenetic effect of anti-phospholipid antibodies on microcirculation: direct damage of endothelial cells through upregulation of adhesion molecules, platelet activation, interaction with elements of the coagulation system and activation of the complement components. The relationship between microangiopathy and the presence of antiphospholipid antibodies could be explained by this cascade of pathologic changes [9,115].

A correlation between the abnormal capillaroscopic pattern and other SLE specific autoantibodies (anti-dsDNA, anti-Sm) [115] could be found, as well as with the disease activity evaluated by

different disease indices (SLEDAI, ECLAM) [67,115]. Besides, an association of abnormal capillaroscopic findings, especially a decreased capillary density and a reduced diffusion capacity, could be verified. It was speculated that the reduced number of capillaries in the nailfold area may be an indicator for pulmonary capillary loss [56,109]. Nailfold capillaroscopy is thought to be useful for the evaluation of microcirculation in SLE patients especially in those with secondary RP.

7. 1. 3. Undifferentiated connective tissue disease

The term UCTD is used to describe a group of patients with features of systemic autoimmune disease, that lacks the characteristics of a well-defined rheumatic disorder. Some of these patients (1/4 to 1/3) develop a distinct rheumatic entity during the follow-up, the most frequent being SSc, SLE, RA and Sjögren's syndrome, but the majority of patients remain in a stable clinically and laboratory condition in the scope of the term UCTD. Nagy et al. found a "scleroderma-like" capillaroscopic pattern in 13.8% of 65 patients with "UCTD" [101].

7. 1. 4. Inflammatory arthritis

7. 1. 4. 1. Rheumatoid arthritis

The prevalence of RP in RA is not well-defined. Some authors consider that such an association is quite rare [122]. On the other hand, other authors include RA among the rheumatic diseases associated with RP [17,79]. Grassi et al. (1994, Italy) found a low incidence of RP in RA - 4.6 %, (19/411). The higher prevalence of RP in men with RA (7.5%) than in women (3.2%) was interesting. In comparison, in a cohort of 919 patients with osteoarthritis, a global tendency of a female predominance of RP was observed. The higher prevalence of RP in men with RA has been explained by the authors with a higher association of RA with secondary vasculitis in men [54]. These results are in agreement with the findings of Carrol et al. (1981, North Australia), who found a manifestation of RP in 2.7% of 141 patients with RA [27]. In a French population of RA patients, Saraux and co-workers found a higher prevalence of RP in RA (17.2%, 54/322) [117]. The contradictory literature data about the prevalence of RP in RA require future studies in different populations of

RA patients.

In 31 RA patients, Redisch and co-authors found the following abnormal capillaroscopic findings: elongated capillaries, increased tortuosity, prominent subpapillary plexus. A “scleroderma-like” pattern was not observed in RA patients [53,113]. A correlation between abnormal capillaroscopic pattern and increased levels of fibrinogen and other acute-phase reactants (CRP, ESR) could be found in patients with primary and secondary RP [131].

7. 1. 4. 2. Psoriatic arthritis

The first observation of capillaroscopic findings in PsA was performed by Redisch et al. (1970), using light microscope. The most frequent capillaroscopic changes were meandering capillaries and tight terminal convolutions [113]. In PsA patients with nail involvement, independent of presence or absence of arthritis of distal interphalangeal joints, a lower mean capillary density has been found as compared with healthy controls. In PsA patients with distal interphalangeal joints involvement, independent of the

concomitant nail damage, a decreased diameter of the arterial and the venous limb of the capillary loop has been observed [16]. In an Italian study, a decreased capillary diameter and length in RA-like form of PsA was reported [116]. An association between psoriasis, PsA and RP is reported as individual cases as well as association of psoriasis and PsA with autoimmune disease like SSc, SLE, etc. Of note, systemic studies in the current literature addressing the frequency of RP in PsA are not available [58,114].

7. 1. 4. 3. Early arthritis

According to the EULAR recommendations (2007) for the management of early arthritis, exclusion of diseases other than RA requires careful medical history, clinical examination, and at least the following laboratory tests: complete blood cell count, urine analysis, transaminases and ANA test. These investigations are necessary to differentiate RA from other rheumatic diseases such as CTD, reactive arthritis etc. because of the different prognosis and treatment [32]. The role of capillaroscopy in early arthritis has not been studied and

discussed in the current rheumatologic literature including in the above mentioned EULAR recommendations.

7. 1. 5. Other rheumatic diseases

7. 1. 5. 1. Primary RP

The diagnosis of primary RP can be made in these cases, in which no underlying causes for development of the vasospastic disorder can be identified. Women are 4 to 20 times more likely than men to develop primary RP. The onset of the disease is usually at puberty and is more frequent in certain families. Symmetrical vasospastic attacks and a benign course without trophic lesions is typical [17,63,122,132,135]. Primary RP is often associated with migraine, retinopathy and Prinzmetal's angina. This supports the hypothesis that RP is a systemic disorder with spasms not only of the peripheral arteries, but also with spasms of the coronary vessels, the arterioles of the lung, the brain, the retina and the gastrointestinal tract [75,129,135].

The absence of an abnormal capillaroscopic pattern is one of the diagnostic criteria for primary RP.

For the diagnosis of primary RP, the lack of the following criteria (Le Roy and Medsger) is required a/ digital ulcerations and gangrenes b/ elevated ESR; c/ positive test for ANA with a high titer d/ abnormal capillaroscopic pattern [79]. Capillaroscopic pattern in primary RP is not specific and the demonstrated capillaries are normal in number and size. The mean capillary diameter, capillary density and capillary morphology do not differ significantly from those of healthy subjects. The capillary diameter can be slightly enlarged, but it does not have a diagnostic value [19]. In primary RP patients, Bukhari et al. [23] and Anderson et al. [4] found enlarged capillary loops when compared with healthy subjects, which suggests minimal microvascular abnormalities. In a part of primary RP patients without signs and symptoms of a CTD, capillaroscopic pattern may be abnormal [90,101]. Primary RP patients with abnormal capillaroscopic changes may develop a connective autoimmune disorder [23,90]. Even the detection of a single loop with diameter $> 50\mu\text{m}$ should be considered as a potential marker of microangiopathy and an indicator for future development

of CTD. It has been suggested that the appearance of dilated capillaries is due to a local response to tissue hypoxia [34,37,38]. Blockmans et al. found enlarged capillaries in 100% of SSc patients, 56% of patients with mixed connective tissue disease, and 86% of DM patients [18,34]. RP may be an isolated complaint or a first symptom of CTD, so patients with manifestation of RP have to be regularly examined [34,110,122,132,148]. Over a 10-year follow-up period, the frequency of development of connective autoimmune disease is increasing from 5 to 19% [110,148]. The capillaroscopic pattern of the same digit remains surprisingly constant for an extended period of time in healthy individuals, while appearance of abnormal findings inherits a positive predictive value of 47% for the development of CTD. In combination with a positive ANA test and the presence of a RF, the predictive value increases up to 55% [74].

Therefore, nailfold capillaroscopy is of crucial importance for the differentiation of primary and secondary RP in rheumatic diseases particularly the scleroderma - spectrum disorders. In presence of RP, a follow-up nailfold capillaroscopic analysis is

recommended to be performed every 6 months [17,19,37,38,68,71].

7. 1. 5. 2. Primary fibromyalgia

Fibromyalgia is an idiopathic, chronic, nonarticular pain syndrome defined by widespread musculoskeletal pain and multiple tender points [43,146]. Secondary fibromyalgia is a common finding in most rheumatic diseases e. g., RA, SLE, Sjögren syndrome [145].

RP is a common finding in patients with primary and secondary fibromyalgia and occurs in about 30% of patients [77,146]. However, capillaroscopic changes in fibromyalgia are not specifically studied and are not well-defined in the current literature. Frödin et al. (1988) published their observation on 10 patients with primary fibromyalgia. The authors have found moderate enlargement of the capillary loops in the examined group of patients [46]. Morf et al. (2005) found in 10 women with fibromyalgia significantly fewer capillaries in the nailfold area and more capillary dilations in comparison with age- and sex-matched controls [97].

7. 1. 5. 3. *Paraneoplastic RP*

The association of cancer with autoimmune phenomena is well known in different rheumatic diseases such as PM/DM, Sjögren's syndrome, inflammatory arthritis, SLE, RP, hypertrophic osteoarthropathy, polymyalgia rheumatica, SSc, scleroderma-like syndromes [13,15,29,103,104]. Rheumatic disorders associated with cancer include different manifestation, most of which have no features distinguishing them from idiopathic rheumatic diseases. Neoplastic lesions may evoke the paraneoplastic rheumatic syndromes or to be a complication of the chronic rheumatic diseases or its treatment. They may precede the clinical manifestation of the neoplasm, occur concomitantly or after its diagnosis [29,103]. Maurice Raynaud (1862) and Trousseau (1865) described the association between malignancies and peripheral blood vessel diseases. Ischemia of the fingers has been reported in patients with carcinomas of the breast, stomach and the esophagus, in leukemia patients and in patients with other malignancies. This phenomenon is caused by the secretion of vasoactive substances by the tumor cells and the respective immune

response of the organism. A newly appeared RP with a late onset after the age of 60 may be a key hint for an underlying malignancy [84,111]. RP may be an isolated symptom or a manifestation in the context of a paraneoplastic rheumatic syndrome. However, the capillaroscopic pattern in paraneoplastic RP has not been studied and defined in the current literature.

8. Capillaroscopic changes in arterial hypertension

In essential AH patients, a rarefaction of capillaries of the nailfold and the forearm is found as well as tendency to vasospasm. The changes are structural rather than functional [5,51,112]. In patients with established disease, Gasser and Prasad announce similar data for a capillary reduction of 15-20% [51,112]. Analogous changes are observed in conjunctival vessels [126]. A correlation between the mean capillary density and the values of diastolic blood pressure could be observed [5]. A capillary rarefaction has also been found in borderline essential AH [6]. A reduced capillary count precedes development of AH and is found in healthy

subjects with predisposition to high blood pressure, who are offsprings of AH patients. This suggests that microvascular abnormalities in AH patients are primary, probably genetically determined [7,105]. It is hypothesized that reduced capillary count in hypertensive subjects is a result of defective angiogenesis. These patients are usually born with lower birth weight and are more obese than normotensive controls. Probably, because of faster rates of growth in later life, in hypertensive subjects more capillaries have to be recruited to supply perfusion. This probably results in structural microvascular changes and AH [10,105]. The available studies address AH patients, who do not receive antihypertensive therapy. There are sparse data about microvascular findings in treated patients. Weinbacher et al. (1994) after 6 weeks' treatment with 5 mg cilazapril plus 12.5 mg hydrochlorothiazide did not find significant changes in morphological capillaroscopic parameters in 17 AH patients [144].

9. Analysis of the capillaroscopic images

As mentioned above, some of the capillaroscopic

parameters such as capillary width, length, mean capillary density can be exactly measured quantitatively by the current available software programs, while other parameters e.g., shape, distribution and haemorrhages are evaluated qualitatively. Counting the number of the haemorrhages, ramified capillaries per mm and evaluation of the degree of the derangement are methods for semiquantitative analysis of the capillaroscopic image. Nowadays, there are no guidelines for the application of the qualitative and quantitative analysis of the capillaroscopic images in the rheumatologic practice [91,107,119].

Sulli et al. (2008) offered an index for semiquantitative assessment of capillaroscopic changes in SSc. The examined fingers are 2nd, 3rd, 4th and 5th. The following capillaroscopic parameters were evaluated – dilated, giant capillaries, haemorrhages, loss of capillaries, disarrangement, capillary ramification. A four-degree scale 0-3 was used for rating. The authors suggested the nailfold area to be divided in 4 fields each with 1 mm length, oriented according to the middle of the nailfold. The sum of the eight examined digit at the end

is divided to 8 and this result is the mean score of the capillaroscopic image. 90 SSc patients were evaluated by nailfold videocapillaroscopy for an average of 72 months. The capillaroscopic score was found to be a sensitive tool to quantify and monitor the SSc microvascular damage [134].

10. State of the art and actuality of the subject

Several conclusions may be made from the analysis of the current literature. The nailfold videocapillaroscopy is currently used particularly for the diagnosis of SSc, differentiation of primary RP and secondary RP in SSc and scleroderma-spectrum disorders. Although its potential for differentiation of RP in different forms of secondary RP in rheumatic diseases is suggested, it is still insufficiently applied for that reason in clinical rheumatological practice.

Conclusions

1. Nailfold capillaroscopy is a non-invasive, inexpensive, easy to repeat imaging technique, which is of considerable importance for the evaluation of microcirculation in vivo with high reproduction and low price.

2. The main indication for the investigation in rheumatology are patients with RP, who are a common diagnostic problem in rheumatologic practice. The method is of crucial importance for the diagnosis and the differentiation of primary RP from secondary RP in SSc and scleroderma-spectrum disorders, which is of crucial importance because of the different severity, prognosis and therapeutic approach. Thus, capillaroscopic examination should be performed in all patients with RP even when there are no clinical and laboratory evidence for CTD, because the abnormal capillaroscopic pattern inherits a high positive predictive value for the development of systemic rheumatic disease.

3. The inclusion of the abnormal capillaroscopic pattern as a diagnostic criterion in patients with SSc increases the sensitivity of ACR classification criteria for

SSc and improves the possibilities for early diagnosis of the disease.

4. There are no data about the capillaroscopic pattern of the feet in SSc patients.

5. The absence of an abnormal capillaroscopic pattern is one of the diagnostic criteria for primary RP.

6. Interestingly, a correlation between capillaroscopic pattern and clinical presentation, laboratory findings and disease activity may indicate common pathways.

7. There are limited data about capillaroscopic findings in patients with rheumatic diseases without RP e. g., SLE, UCTD, inflammatory arthritis, fibromyalgia.

8. AH is a co-morbidity in a high number of patients with rheumatic diseases. In the current literature, it has been known that low mean capillary density can be found in different regions of the body in these patients. This phenomenon has been observed also in the area of the nailfold of patients, who are not treated with antihypertensive drugs. Sparse data about capillary density in the nailfold area in patients treated with

antihypertensive drugs exist.

9. No guidelines for the application of the qualitative and quantitative methods for analysis of the capillaroscopic images in rheumatologic practice exist.

These conclusions stimulated the work presented in this dissertation.

CHAPTER II

AIM AND TASKS OF THE DISSERTATION

1. The objective of the dissertation

To establish a more detailed view on the role of capillaroscopy in different unclear rheumatologic settings.

2. Tasks

1. Studying the role of capillaroscopy in SSc.

1. 1. Confirmation of the known specific capillaroscopic pattern in SSc.

1. 2. Studying the association between capillaroscopic pattern and the presence of digital ulcers.

1. 3. The high specificity of capillaroscopic pattern in SSc raised the question about presence of microvascular changes in the nailfolds of the toes.

2. Studying the role of capillaroscopy in other common CTD.

2. 1. Role of capillaroscopy in SLE.

2. 1. 1. Studying the association of capillaroscopic pattern in SLE patients with the immunologic profile.

2. 2. Role of capillaroscopy in UCTD.

3. Studying the role of capillaroscopy in inflammatory arthritis.

3. 1. Role of capillaroscopy in RA with and without RP.

3. 2. Role of capillaroscopy in PsA.

3. 3. Role of capillaroscopy in early arthritis.

4. Role of capillaroscopy in other rheumatic diseases.

4. 1. Role of capillaroscopy in primary RP.

4. 2. Role of capillaroscopy in primary fibromyalgia.

4. 3. Role of capillaroscopy in paraneoplastic RP.

5. Role of capillaroscopy in AH.

6. Comparison of the qualitative and quantitative analysis of key capillaroscopic parameters in patients with common rheumatic diseases e. g., SSc, SLE, UCTD, different forms of overlap, RA and primary RP.

Assessment of the reproducibility of the qualitative evaluation of the capillaroscopic parameters, performed by two different investigators.

CHAPTER III

MATERIALS AND METHODS. INCLUSION AND EXCLUSION CRITERIA

1. Patients

The study includes 297 patients with rheumatic diseases, who were examined during routine in- and outpatient consultation in the Department of Rheumatology and Clinical Immunology in Kerckhoff Clinic, Bad Nauheim. The examined patients are from the following groups:

1. 36 patients with SSc, diagnosed according to the current ACR classification criteria, 1980 [94], 30 patients with limited SSc, 5 with diffuse SSc and 1 with overlap syndrome, 30 female and 6 male patients, mean age 56 ± 14 years. The severity of RP in the hands and feet was assessed with VAS (100mm) by the physician and the patient. The patients were asked by the physician - “please, evaluate the severity and frequency of RP in the last month according to the disability that vasospastic attacks cause to your everyday activities“. The presence of digital ulcers of the hands and the feet was documented. The skin score of the fingers and feet was

assessed by the scale used for evaluation of the modified Rodnan skin score: 0 - uninvolved skin, 1-mild, 2-moderate, 3-severe thickening [30].

2. 30 female patients with SLE according to the current ACR classification criteria, 1982 [136]. The mean age of the SLE patients was 49 ± 15.4 years.

3. 31 patients with UCTD. This group of patients manifested with signs of CTD, but did not fulfill the criteria for SSc, SLE or other definite CTD. The mean age of the patients from this group was 50 ± 17 years, 30 females and 1 male.

4. 62 patients with RA according to the current ACR classification criteria, 1987 [8]. The mean age of patients from RA group was 62.8 ± 11.3 years, 47 females and 15 males.

5. 9 female patients with early arthritis, at the time of their first referral to a rheumatologist, with duration of symptoms < 6 months, who did not fulfill the criteria for a definite type of arthritis or CTD and are diagnosed during the follow-up as RA. The mean age of this group was 46.44 ± 13.8 years.

6. 34 patients with RA-like form of PsA and with

subtype of the disease with involvement of the distal interphalangeal joints, who fulfilled the CASPAR criteria [138]. The mean age was 49 ± 12.04 years, 22 females and 12 males.

7. 31 patients with primary RP according to the classification criteria of Le Roy and Medsger, 1992 [79]. The mean age was 47 ± 14 years, 23 females and 8 males.

8. 26 patients with primary fibromyalgia according to the current ACR classification criteria, 1990 [146]. The mean age was 55 ± 10 years, 25 females and 1 male.

9. Paraneoplastic RP – 3 patients.

10. 35 patients with essential mild-to-moderate AH without systemic rheumatic disease on a regular antihypertensive treatment. The mean age was 62.6 ± 11.92 years, 22 females and 13 males.

11. A control group - 43 healthy volunteers without known disease, who did not receive medications. Comparison of the capillaroscopic parameters was made with age- and sex-matched healthy controls, who were specifically chosen for each group of patients.

2. Technical equipment

Nailfold capillaroscopy was performed using a high-end videocapillaroscope Videocap 3.0 (DS Medica, Italy). Measurements were performed with the software programme of the device and all the measurements were made in mm, ($0.001\text{mm}=1\mu\text{m}$). The following capillaroscopic parameters were evaluated:

- 1) distribution
- 2) shape of capillaries
- 3) diameter of the arterial limb of the capillary loop
- 4) diameter of the venous limb of the capillary loop
- 5) capillary length
- 6) mean capillary density
- 7) presence of avascular areas
- 8) presence of haemorrhages
- 9) presence of neoangiogenic capillaries
- 10) visibility of the subpapillary plexus.

As dilated were classified capillaries with a diameter of the arterial limb wider than 0.015mm ($=15\mu\text{m}$) or a venous limb wider than 0.020mm ($=20\mu\text{m}$). As giant capillary loops were classified microvessels with diameter of either an arterial or a

venous limb greater than 0.050mm (=50 μ m). The mean diameter of the arterial and the venous limb was calculated as a mean value of the three widest arterial, respectively venous limbs at their widest part. The length of the capillary loop was measured as the distance between the papillary plexus (if visible) or the visualized base of the capillary loop and the apical part. The mean capillary length was calculated as a mean value of the three longest capillaries. As elongated were classified capillary loops with lengths longer than 0.300mm (=300 μ m). The haemorrhages are the extracapillary brown aggregations of erythrocytes. The mean capillary density was calculated as a number of capillary loops in the distal row per 1 mm. The avascular area was defined as a distance between two adjacent capillary loops from the distal rows greater than 0.5mm (=500 μ m) or above 0.3mm (300 μ m) in the proximal area [119]. Meandering capillaries, presence of more than one capillary loop in a single dermal papilla, ramified and bushy capillaries are the characteristic features of neoangiogenic capillaries and were classified respectively. All observations are performed with the subjects in a constant temperature

setting (22° to 25° C).

3. Immunologic tests

In the group of patients with SLE, the following immunologic tests were examined: ANA immunofluorescence test and antibodies against extractable nuclear antigens e. g., anti-dsDNA, anti-Ro, anti-La, anti-Sm, anti-RNP, anticardiolipin IgG, anticardiolipin IgM, anti- β 2-glycoprotein (IgG, IgM), measured by ELISA method.

4. Other methods

200 capillaroscopic images from 93 patients with different rheumatic diseases were analysed quantitatively and qualitatively by two different investigators. The distribution of the images according to the diagnosis and the microvascular abnormalities was as follows - group 1: 73 images from SSc patients (“scleroderma” type), group 2: 10 images from DM (“scleroderma-like”), group 3: 25 images from UCTD and different forms of overlap (19 “scleroderma-like“), group 4: 26 from SLE, group 5: 46 from RA and group 6: 20 from primary RP. All the

images were mixed and blindly presented to both investigators.

The following major capillaroscopic parameters were evaluated: presence of dilated and giant capillaries, haemorrhages, avascular areas. The above mentioned definitions were used e. g., capillaries with a diameter of the arterial limb wider than 0.015mm (= 15 μ m) or a venous limb wider than 0.020mm (=20 μ m) were classified as dilated. As giant capillary loops were classified microvessels with a diameter of either an arterial or a venous limb wider than 0.050mm (=50 μ m) and as elongated – capillaries with length greater than 0.300mm (=300 μ). The avascular area was defined as a distance between two adjacent capillary loops from the distal rows longer than 0.500mm (=500 μ m) or above 0.300mm (=300 μ m) in the proximal area [117]. The reliability of quantitative and qualitative methods, and the reproducibility of the qualitative assessment performed by two different investigators was evaluated specifically for the “scleroderma” and “scleroderma-like” images and for images of primary RP patients.

i) For comparison of the quantitative and qualitative methods, investigator 1 assessed *presence of dilated, giant capillaries and avascular areas, according to the above-mentioned definitions* by the available software programme and his estimates were compared with the results of investigator 2, who assessed the parameters qualitatively.

ii) For evaluation the reproducibility of the qualitative method performed by two different investigators, the mixed and blindly presented capillaroscopic images, were evaluated qualitatively by the investigator 1 and investigator 2 for the presence of the following capillaroscopic changes - *dilated capillaries, giant capillaries, haemorrhages and avascular areas*.

5. Statistical methods

For statistical analysis of the data, variational analysis, t-criterion of V. Goset (Student-Fisher) and χ -square test were used. Results are shown as mean value/average \pm SD. The values of $p < 0.05$ were

considered as statistically significant.

The study has been approved by the local ethical committee and all patients signed an informed consent.

6. Inclusion and exclusion criteria

6. 1. Inclusion criteria

1. SSc according to the current ACR classification criteria, 1980 [94].

2. SLE according to the current ACR classification criteria, 1982 [136].

3. Patients with UCTD are defined as having features of systemic rheumatic disease, but who did not fulfill the accepted diagnostic criteria of a distinct rheumatic disease.

Patients with overlap syndrome are referred to the entity, which dominated at clinical presentation.

4. RA according to the current ACR classification criteria, 1987 [8].

5. PsA according to the CASPAR criteria [138].

6. Patients with early arthritis. at the time of their first referral to a rheumatologist, with duration of symptoms < 6 months, who did not fulfill the criteria for

a definite type of arthritis or CTD.

7. Primary RP according to classification criteria of Le Roy and Medsger, 1992 [79].

8. Patients with primary fibromyalgia according to the current ACR classification criteria, 1990 [146].

9. Healthy controls - employees from the hospital and their relatives.

Comparison of the capillaroscopic parameters was made with age- and sex-matched healthy controls, who were specifically chosen for each group of patients. The data of the patients and the age- and sex-matched healthy controls are shown in Table.1.

Number (n) of patients from each group/number of controls	Age(average±SD)	Sex (females/males)
SSc patients, n=36 Healthy controls, fingers examination, n=33	56±14 54.43±14.09 (p>0.05)	30 females, 6 males 31 females, 2 males (p>0.05)
SSc patients, n=36 Healthy controls, toes examination, n=22	56±14 51.54±12.49 (p>0.05)	30 females, 6 males 19 females, 3 males (p>0.05)
SLE, n=30 Healthy controls, n=34	49±15.4 49.76±15.98 (p>0.05)	30 females 33 females, 1 male (p>0.05)
UCTD, n=31 Healthy controls, n=34	50±17 49.76±15.98 (p>0.05)	30 females, 1 male 33 females, 1 male (p>0.05)
RA, n=62 Healthy controls, n=24	62.8±11.3 61.16±9.16 (p>0.5)	47 females, 15 males 20 females, 4 males (p>0.05)
PsA, n=34 Healthy controls, n=43	49±12.04 49.30±16.09 (p>0.05)	22 females, 12 males 34 females, 9 males (p>0.05)
Early arthritis, n=9 Healthy controls, n=22	46.44±13.8 47.27±10.40 (p>0.05)	9 females 22 females (p>0.05)
Primary RP, n=31 Healthy controls, n=43	47.3±14.68 49.30±16.09 (p>0.05)	23 females, 8 males 34 females, 9 males (p>0.05)
Primary fibromyalgia, n=26 Healthy controls, n=31	55.76±10.12 53.67±13.64 (p>0.05)	25 females, 1 male 30 females, 1 male (p>0.05)
Arterial hypertension, n=35 Healthy controls, n=24	62.6±11.92 61.16±9.16 (p>0.05)	22 females, 13 males 20 females, 4 males (p>0.05)

Table. 1. Number, age and sex of the included groups of patients and the age- and sex-matched controls.

6. 2 Exclusion criteria

Exclusion criteria for healthy controls group was *history of vasospasm, rheumatic or other known diseases, taking any medications*. Specific history for *familial predisposition for AH in first degree relatives* was undertaken and it was included also as an exclusion criterion. Defective angiogenesis in obesity was also taken into account and *body mass index above $> 25\text{kg/m}^2$* was included also as an exclusion criterion for this group. In 22 of the healthy individuals, we performed capillaroscopic examination of the toes. Here, the presence of chronic arterial or venous insufficiency were additional exclusion criteria.

CHAPTER IV

RESULTS

1. Systemic sclerosis

1. 1. Capillaroscopic pattern of the hands in systemic sclerosis patients

RP was found as clinical symptom in 100% (36/36) of the examined SSc patients. “Scleroderma” type capillaroscopic pattern with dilated and giant capillaries, haemorrhages, avascular areas and neoangiogenesis was found in 97.2% (35/36) of the cases.

The mean diameters of the arterial ($0.035\pm 0.013\text{mm}$) and the venous limb ($0.053\pm 0.021\text{mm}$) in SSc were significantly wider as compared with the respective values in healthy controls ($0.012\pm 0.001\text{mm}$ for the arterial limb and $0.017\pm 0.001\text{mm}$ for the venous limb), ($p < 0.05$). The mean length of the capillary loop ($0.284\pm 0.109\text{mm}$) was found to be significantly longer as compared with those in healthy controls ($0.199\pm 0.072\text{mm}$), ($p < 0.05$). The mean capillary density in SSc patients (5.11 ± 1.72 capillaries/mm; range 4-10) was found to be significantly lower as compared with

those in healthy subjects (10.3 ± 0.59 capillaries/mm, range 10-12), ($p < 0.05$). A prominent subpapillary plexus was found in 17% (8/36), which was significantly lower as compared with healthy volunteers (33.3%, 11/33), ($p < 0.05$).

In SSc patients with a duration of the disease less than 3 years (mean duration 1.8 ± 0.9 years, range 0.75-3), in 50% of the cases (5/10) an “early” phase “scleroderma” type capillaroscopic pattern was found. It is characterized by the presence of dilated capillaries, single giant capillaries, single haemorrhages, without capillary loss and with relatively preserved distribution as mentioned above (Fig. 1). In the other 50% (5/10) of the patients from this group an “active” phase “scleroderma” pattern was observed (Fig. 2) with the characteristic features of this phase – frequent giant capillaries and haemorrhages, avascular areas and different degree of derangement. In the group of SSc patients with duration of the disease of more than 3 years (mean duration 12.4 ± 6.7 years, range 5-27), in 26.9 % (7/26) it was found a “late” phase “scleroderma” capillaroscopic pattern, characterized by presence of extensive, “desert-

like” avascular areas, neoangiogenic capillaries, severe derangement, absence of giant capillaries and haemorrhages (Fig. 3). In 61.5% (16/26) of the patients from this subgroup, an “active” phase “scleroderma” type capillaroscopic pattern was found, in 7.7% (2/26) - an “early” phase and in 3.8% (1/26) - the images were not evaluated because of poor visualization.

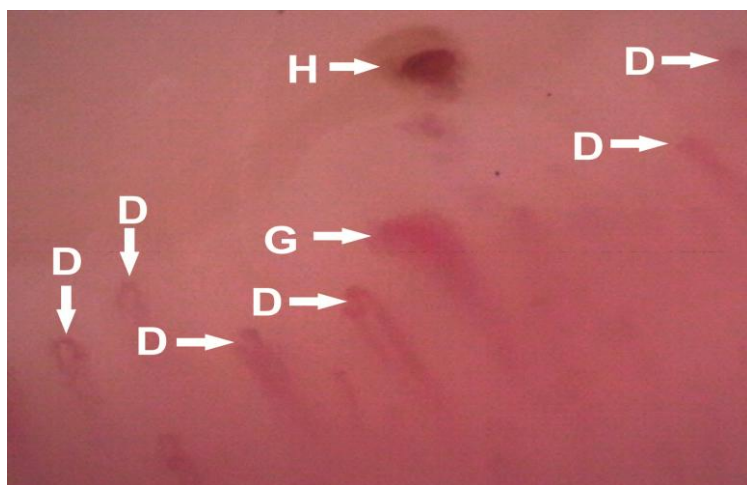


Fig. 1. “Scleroderma” type capillaroscopic pattern, an “early” phase; D-dilated capillaries, G – giant capillaries, H – haemorrhage.

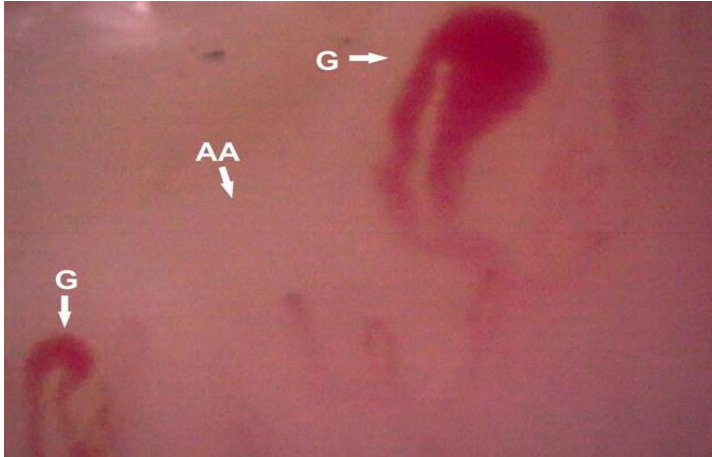


Fig. 2. "Scleroderma" type capillaroscopic pattern, an "active" phase; G – giant capillaries, AA - avascular area.

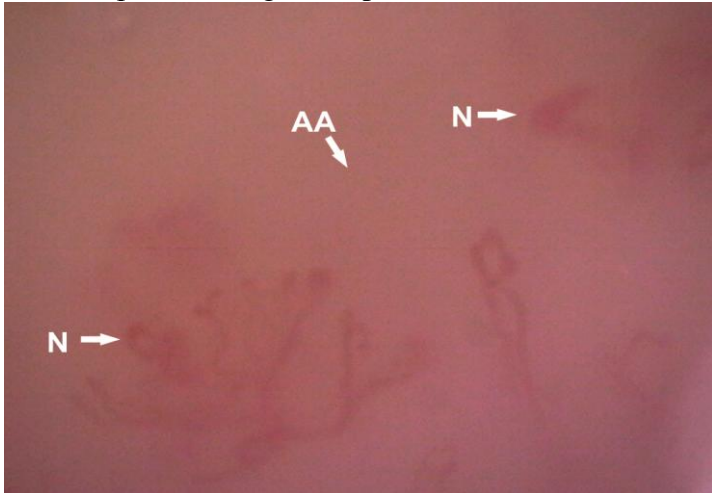


Fig. 3. "Scleroderma" type capillaroscopic pattern, a "late" phase; AA – avascular area, N – neoangiogenic capillaries.

1.2. Association between capillaroscopic pattern and presence of digital ulcers in systemic sclerosis

Digital ulcers at the hands were present in 36.1% (13/36) of the SSc patients. In all of them (13/13), an “active” phase “scleroderma” pattern was observed, characterized by presence of frequent giant capillaries, haemorrhages and avascular areas (Fig. 4). An “active” phase “scleroderma” pattern was found and in other 73.9% (17/23) of patients without digital ulcers ($p>0.05$).

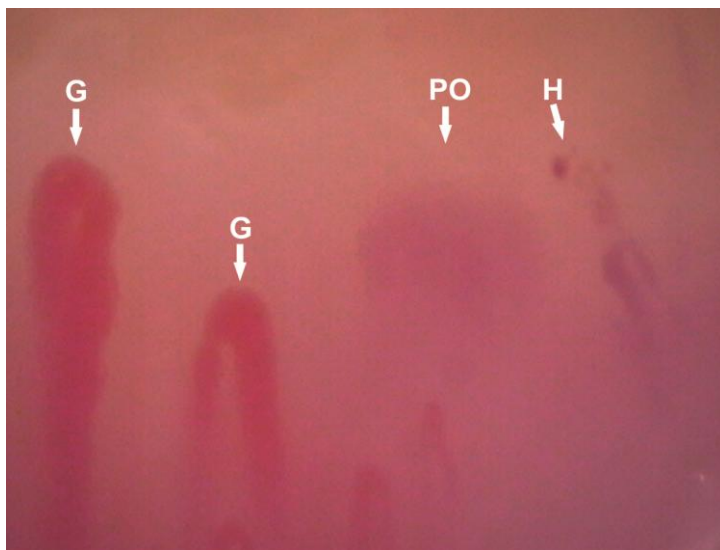


Fig. 4. “Scleroderma” type capillaroscopic pattern, an “active” phase of the finger with active digital ulcer; G - giant capillaries, H - haemorrhage, PO – pericapillary oedema.

1. 3. Capillaroscopic pattern of the toes in systemic sclerosis patients

100% (36/36) of the patients reported about symptoms of RP in the hands and 94.4% (34/36) reported episodes of RP in the feet, but the difference was not significant ($p>0.05$). In the vast majority of patients with RP symptoms of both hands and feet, the symptoms were more severe at the hands (82%, 28/34). Digital ulcers of the fingers were found in 36% (13/36) of the cases and in 8.3% (3/36) in the toes ($p<0.05$). The skin score of the hands and fingers (2.05 ± 0.67) was significantly higher than that in the feet (0.69 ± 0.57), ($p<0.05$).

Nailfold capillaroscopy of the hands of the SSc patients showed the classic “scleroderma” type capillaroscopic pattern in 97.2% (35/36), with the typical features - dilated and giant capillaries, haemorrhages, avascular areas and neoangiogenesis. In contrast, in the toes, the “scleroderma” type capillaroscopic pattern was found only in 66.7% (24/36) of the patients, and this difference in frequency of the specific changes of the fingers and toes was statistically significant ($p<0.05$), (Fig. 5,6,7).

With respect to distinct differences, in the toes, the dilated capillaries were found in 72.2% (26/36) of the cases, giant capillaries - in 30.6% (11/36), haemorrhages - in 8.3% (3/36), avascular areas - in 41.7% (15/36), and neoangiogenesis - in 22.1% (8/36). This difference in frequency of the distinct capillaroscopic parameters in the toes and fingers of SSc patients was statistically significant for all parameters (Fig. 8, Table 2).

In addition, the mean values of the arterial diameter, the venous diameter, and the capillary length were statistically significantly higher in the fingers when compared with the respective values of the toes. The mean capillary density was found to be significantly lower in the hands compared with those of toes ($p < 0.05$), (Table 3).

When comparing the mean values of the main capillaroscopic parameters in the toes of the SSc patients with those of the toes of healthy controls, it was observed that the mean diameter of the arterial and the venous capillary limb was significantly wider in SSc patients ($p < 0.05$). The mean capillary length was found to be longer in SSc patients compared with those in healthy

individuals, but the difference did not reach statistical significance ($p>0.05$). Furthermore, the mean capillary density of the toes of SSc patients was found to be significantly lower (7 ± 3 capillaries/mm) than that of the toes of healthy volunteers (10 ± 1.13 capillaries/mm), ($p<0.05$), (Fig. 9, Table 4).

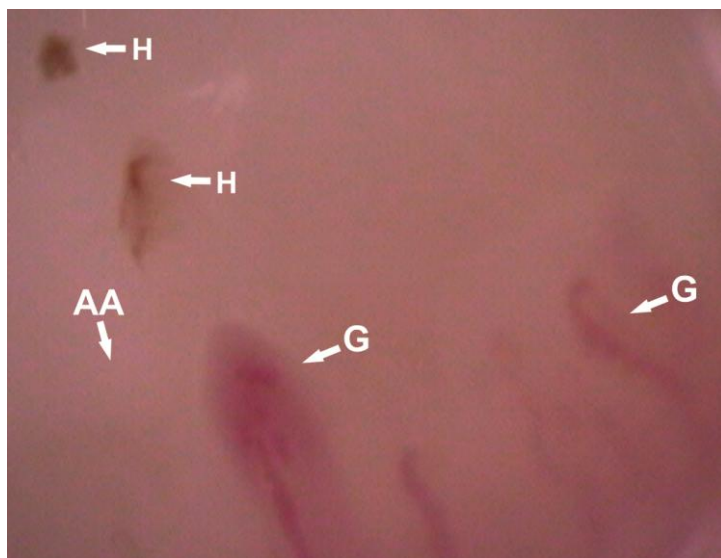


Fig. 5. "Scleroderma" type capillaroscopic pattern, an "active" phase of the toe of 48-year-old male patient with limited form of SSc; G - giant capillaries, H - haemorrhages, AA - avascular area.

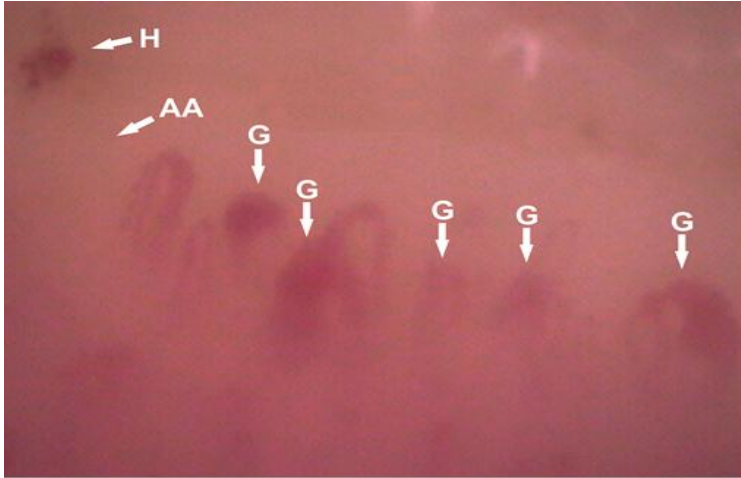


Fig. 6. "Scleroderma" capillaroscopic pattern, an "active" phase of the finger of the same patient, presented at Fig. 5; G - giant capillaries, H - haemorrhage, AA – avascular area.

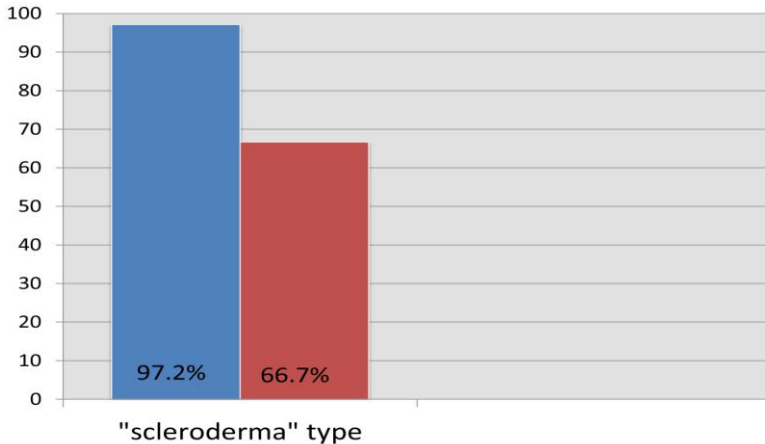


Fig. 7. The frequency of the "scleroderma" type capillaroscopic pattern of the fingers (blue column) and toes (red column) in SSc patients.

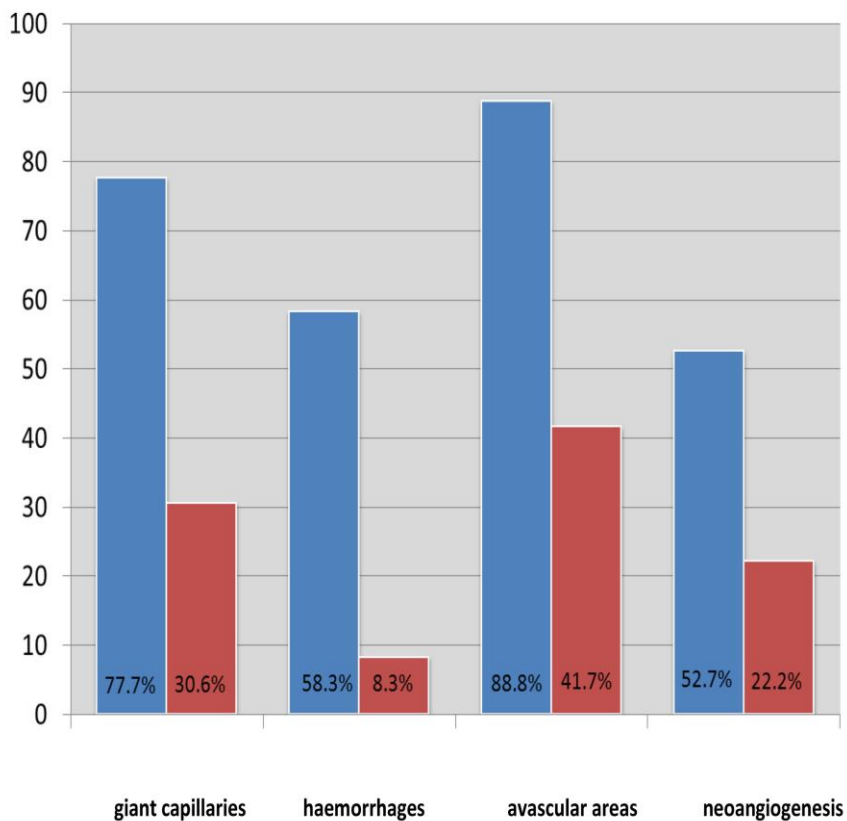


Fig. 8. The frequency of the distinct abnormal capillaroscopic parameters in the context of the “scleroderma” type pattern in the fingers (blue column) and toes (red column) of SSc patients.

Fingers/Toes Capillaroscopic parameters	Fingers	Toes
Dilated capillaries $\chi^2=8.69, p<0.05$	97.2% (35/36)	72.2% (26/36)
Giant capillaries $\chi^2=16.16, p<0.05$	77.7% (28/36)	30.6% (11/36)
Haemorrhages $\chi^2=18.06, p<0.05$	58.3% (21/36)	8.3% (3/36)
Avascular areas $\chi^2=17.7, p<0.05$	88.8% (33/36)	41.7% (15/36)
Neoangiogenesis $\chi^2=7.17, p<0.05$	52.7% (19/36)	22.2% (8/36)

Table 2. The frequency of the capillaroscopic parameters of the “scleroderma” type pattern in the fingers and toes of SSc patients.

Fingers/Toes	Fingers	Toes
Mean values of the capillaroscopic parameters		
Mean diameter of the arterial limb (p<0.05)	0.035±0.013mm	0.021±0.009mm
Mean diameter of the venous limb (p<0.05)	0.052±0.020mm	0.037±0.04mm
Mean capillary length (p<0.05)	0.284±0.11mm	0.200±0.11mm
Mean capillary density (p<0.05)	5±1.7 capillaries/mm	7±3 capillaries/mm

Table 3. Comparison of the mean values of the main capillaroscopic parameters in the fingers and toes of SSc patients.



Fig. 9. Normal capillaroscopic pattern of the toe of a healthy volunteer.

Mean values of the capillaroscopic parameters	Toes - SSc patients	Toes - healthy volunteers
Mean diameter of the arterial limb (p<0.05)	0.021±0.009mm	0.012±0.002mm
Mean diameter of the venous limb (p<0.05)	0.037±0.04mm	0.017±0.002mm
Mean capillary length (p>0.05)	0.200±0.11mm	0.165±0.09mm
Mean capillary density (p<0.05)	7±3 capillaries/mm	10±1.13 capillaries/mm

Table 4. Comparison of mean values of the main capillaroscopic parameters at the toes of SSc patients and at the toes healthy volunteers.

2. Capillaroscopic pattern in systemic lupus erythematosus

RP was found in 73% (22/30) of the cases in the group of patients with SLE, and in 10% (3/30) vasculitis of peripheral vessels was presented. The most frequent capillaroscopic changes in SLE patients were the presence of elongated capillaries in 43% (13/30), an increased tortuosity in 70% (21/30) and a prominent

subpapillary plexus in 60% (18/30) of the cases. In 80% (24/30) of the patients, dilated capillaries were found, in 6.6% (2/30) - giant capillary loops and in 16.6% (5/30) - haemorrhages. The mean capillary diameters of the arterial ($0.019\pm 0.006\text{mm}$) and the venous limb ($0.027\pm 0.007\text{mm}$) in the examined group of patients were significantly wider than the values in age and sex-matched healthy controls ($0.012\pm 0.001\text{mm}$ for the arterial limb and $0.017\pm 0.002\text{mm}$ for the venous limb respectively), ($p<0.05$). The mean capillary length in SLE patients ($0.245\pm 0.111\text{mm}$) was found to be longer than those in healthy controls (0.199 ± 0.071), but the difference was not statistically significant ($p=0.0505$). The mean capillary density in SLE patients (8 ± 1.46 capillaries/mm) was significantly lower than those in healthy subjects (10 ± 0.59 capillaries/mm), ($p<0.05$).

In 50% of the patients a “SLE” type capillaroscopic pattern (with elongated capillaries, increased tortuosity, dilated capillaries and prominent subpapillary plexus) was found (Fig.10). Positive tests for ANA were detected in 73.3% (11/15) of the patients with “SLE” type capillaroscopic pattern. In 54% (6/11)

the ANA titer was $\geq 1:640$. In 40% (6/15) of the patients with “SLE” type capillaroscopic pattern positive tests for antibodies against extractable nuclear antigens were found, as follows: in 40% (6/15) positive tests for anti-dsDNA, in 33% (5/15) for anti-Ro antibodies, in 20% (3/15) for anti-RNP antibodies. Antiphospholipid antibodies (anticardiolipin antibodies - IgG and IgM and β -2 glycoprotein IgG and IgM classes) were negative in patients with a “SLE” type capillaroscopic pattern.

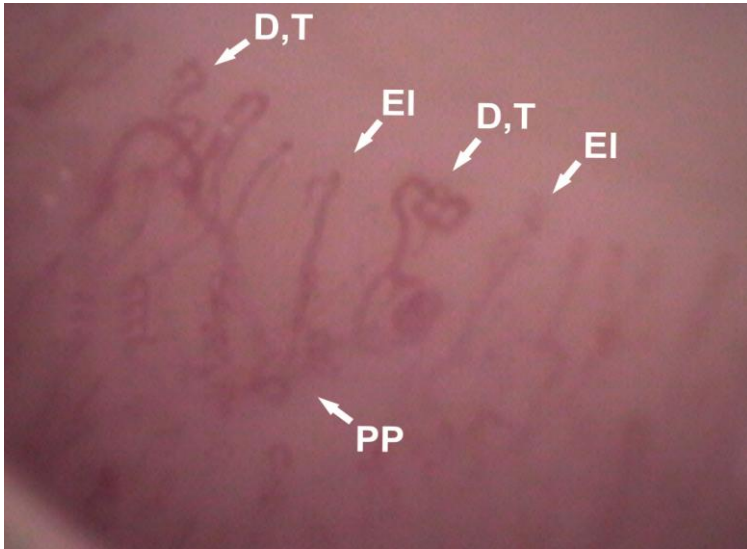


Fig. 10. “SLE” type capillaroscopic pattern in SLE patient with secondary RP, demonstrating dilated and elongated capillaries, increased tortuosity, prominent subpapillary plexus, magnification 200x; D – dilated capillaries, EI – elongated capillaries, T – tortuous capillaries, PP - prominent subpapillary plexus.

In 30% (9/30) of the cases, the capillaroscopic examination revealed “nonspecific changes”, which included some of the above-mentioned changes (Fig. 11).

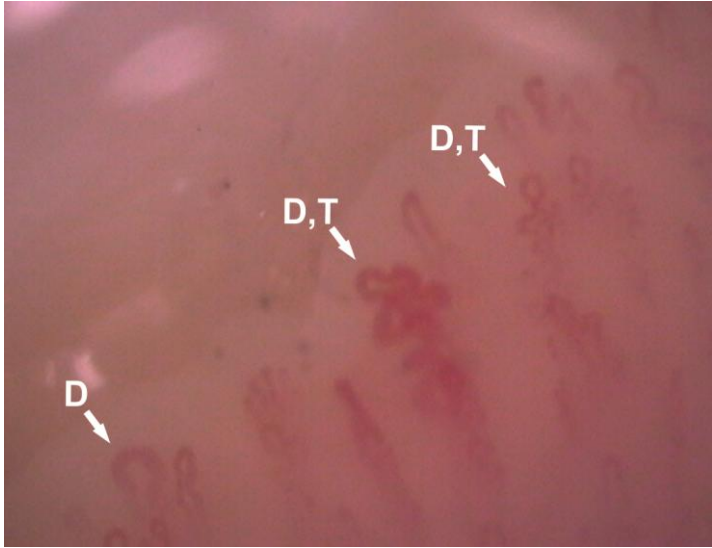


Fig. 11. Nonspecific capillaroscopic changes in SLE patient without RP, demonstrating dilated (D) and tortuous capillaries (T), magnification 200x.

In 6.6% (2/30) of the patients it was found a normal capillaroscopic pattern and in 13.3% (4/30) a “scleroderma-like“ pattern (Fig. 12). In all the patients with “scleroderma-like” capillaroscopic finding positive autoantibodies with a high titer were found (Table 5), without signs for overlap with other CTD. In two out of four patients with such capillaroscopic findings a vasculitis of peripheral vessels was evident.

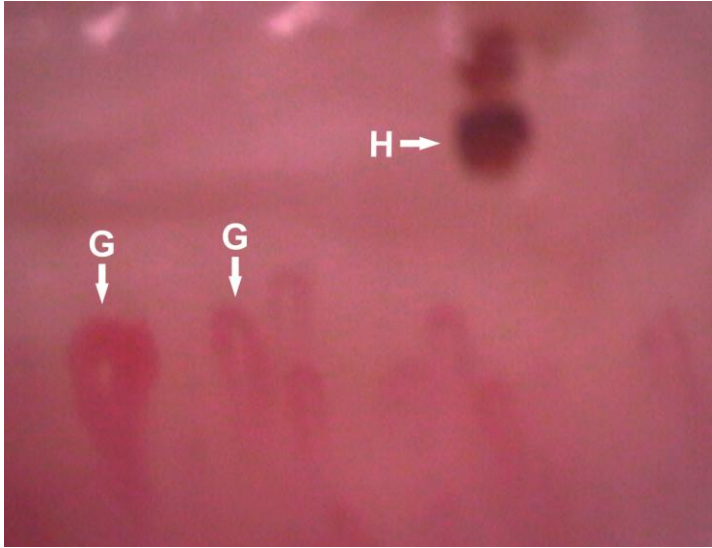


Fig. 12. “Scleroderma-like” capillaroscopic pattern in 40 year-old-female patient with active vasculitis of peripheral vessels and high immunologic activity (case 2, presented in Table 5), magnification 200x; G – giant capillaries, H – haemorrhage.

SLE cases Autoantibodies	Case 1 /with secondary vasculitis/	Case 2 /with secondary vasculitis/	Case 3 /without secondary vasculitis/	Case 4 /without secondary vasculitis/
ANA	1:1280	1:10240	1:1280	1:10240
ENA (<20)	Negative	77.40	144	117
Anti-dsDNA (<100)	Negative	492	105.6	468
Anti-Ro (<20)	Negative	111	Negative	138
Anti-La (<20)	Negative	89.77	Negative	Negative
Anti-Sm (<20)	Negative	Negative	Negative	Negative
Anti-RNP-Sm (<20)	Negative	Negative	>200	Negative
Anti-cardiolipin IgG (<12)	Negative	Negative	28	Negative
Anti cardiolipin IgM (<15)	Negative	Negative	52	Negative
Anti- β 2-glycoprotein (<20)	Negative	Negative	74	Negative
RF (<14)	102	Negative	Negative	Negative

Table. 5. Immunologic profile in SLE patients with a “scleroderma-like” pattern.

The presence of a “scleroderma-like” capillaroscopic pattern is associated in the current literature with presence of anti-RNP antibodies and overlap syndrome [47,56,66,80]. In the examined group of SLE patients such changes were observed in 4 patients, all of whom demonstrated high immunologic

activity, but without signs for overlap with other CTD. Active vasculitis of peripheral vessels was evident in 2 of them.

3. Capillaroscopic pattern in undifferentiated connective tissue disease

RP was found in 77% (24/31) of the patients from this group. A “scleroderma-like” pattern was found in 38% (12/31) of the patients with UCTD (Fig. 13). In 51% (16/31) of the patients from this group, “nonspecific” capillaroscopic findings were observed e. g., dilated, elongated and tortuous capillaries either alone or in different combinations without any specific capillaroscopic pattern. In 9.6% (3/31) of the patients, a normal capillaroscopic pattern was found. The mean diameters of the arterial ($0.020\pm 0.007\text{mm}$) and venous limb ($0.028\pm 0.012\text{mm}$) in patients with UCTD were significantly wider as compared with the respective values in healthy controls ($0.013\pm 0.001\text{mm}$ for the arterial limb and $0.018\pm 0.001\text{mm}$ for the venous limb respectively), ($p<0.05$). The mean length of the capillary loop in UCTD patients ($0.234\pm 0.090\text{mm}$) was found to

be significantly longer as compared with those in healthy controls ($0.197\pm 0.070\text{mm}$), ($p<0.05$). The mean capillary density in patients with UCTD (8.2 ± 1.5 capillaries/mm; range 5-12) was found to be significantly lower as compared with those in healthy subjects (10 ± 0.59 capillaries/mm), ($p<0.05$).

A part of patients with UCTD (over $\frac{1}{4}$ to $\frac{1}{3}$) develop a distinct rheumatic disease during the follow-up, predominantly SSc, SLE or RA, but in the vast majority the clinical and laboratory findings remain unchanged in the scope of the term “UCTD” [101]. For evaluation of the predictive value of capillaroscopic pattern for the development of a distinct rheumatic disorder in patients with UCTD, a longer period of follow-up is necessary.

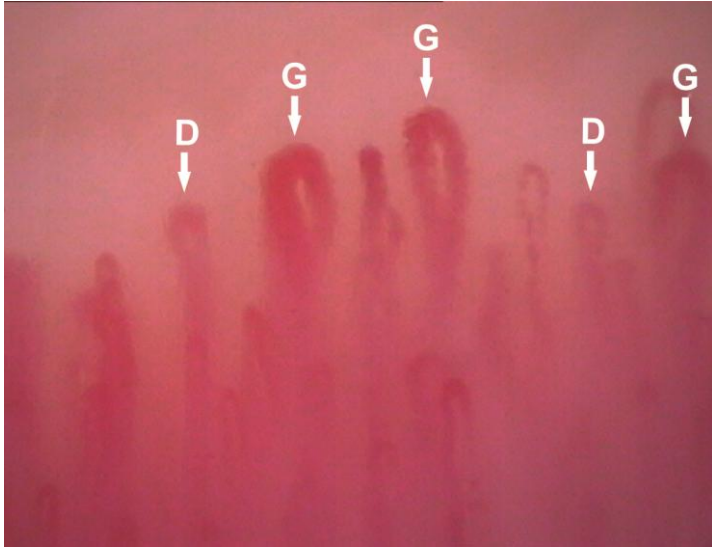


Fig. 13. “Scleroderma-like” capillaroscopic pattern in patient with UCTD and secondary RP, magnification 200x; D – dilated capillaries, G – giant capillaries.

4. Capillaroscopic pattern in inflammatory arthritis

4. 1. Capillaroscopic pattern in rheumatoid arthritis

RP was found in 30.6% (19/62) of the patients with RA, and vasculitis of peripheral vessels – in 3% (2/62) of the cases. The most frequent findings at nailfold capillaroscopic examination were prominent subpapillary plexus in 69% (40/62) and elongated capillaries in 58%

(36/62). They were found statistically significantly more frequent in RA patients as compared with healthy controls ($p<0.05$), (Fig. 14). The mean capillary length in RA patients ($0.265\pm 0.086\text{mm}$) was significantly longer than those in healthy individuals ($0.216\pm 0.081\text{mm}$), ($p<0.05$). The diameters of the arterial ($0.018\pm 0.005\text{mm}$) and the venous limb of the capillary loops ($0.028 \pm 0.009\text{mm}$) in patients with RA and secondary RP were found to be significantly wider as compared with RA patients without RP ($0.016\pm 0.003\text{mm}$ for the arterial limb and 0.022 ± 0.005 for the venous limb), ($p<0.05$). On the other hand, dilated capillaries were found not only in RA patients with RP (78.9%; 15/19), but also in RA patients without clinical symptoms of vasospasm of peripheral vessels (62.8%; 27/43), ($p<0.05$), (Fig. 15, 16). The diameters of the capillary loops of RA patients without secondary RP were also significantly wider than those of healthy controls ($0.012\pm 0.001\text{mm}$ for the arterial limb and $0.017\pm 0.002\text{mm}$ for the venous limb respectively), ($p<0.05$), ($p<0.05$), which may be associated with endothelial damage in different mechanisms in these patients. In 14.5% (9/62) of the RA patients, a

“scleroderma-like” pattern was observed (2 males and 7 females). In one of these cases, an overlap of RA with SLE, secondary RP and secondary vasculitis was found. In the rest, 8/9 patients, no overlap with other CTD was evident. In all RA patients with “scleroderma-like” capillaroscopic pattern (9/9), a secondary RP was present, and in 2/9 - a secondary vasculitis respectively.

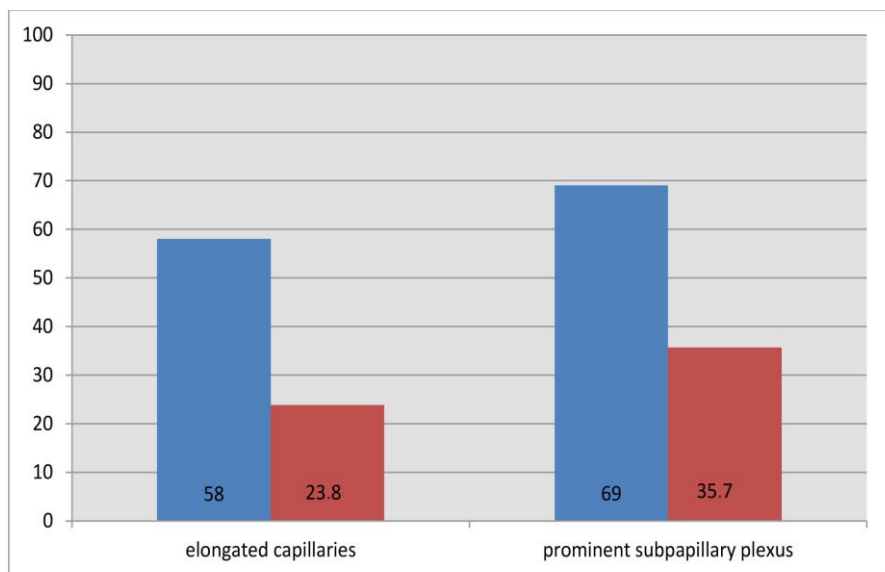


Fig. 14. Comparison of the frequency of the elongated capillaries and the prominent subpapillary plexus in RA (blue column) and in healthy subjects (red column).

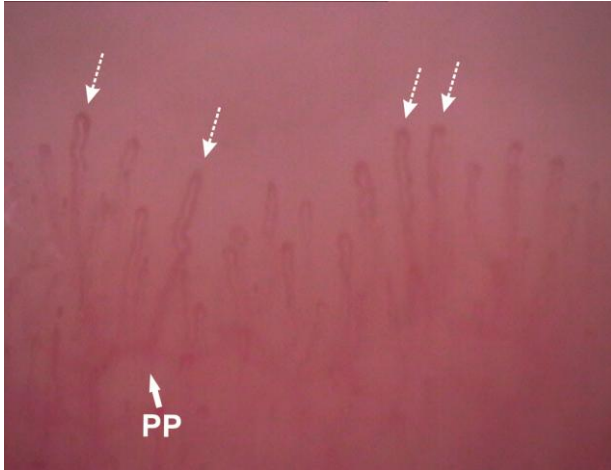


Fig. 15. Capillaroscopic pattern in RA patient without RP, magnification 200x; PP - prominent subpapillary plexus, dotted arrows – elongated capillaries.

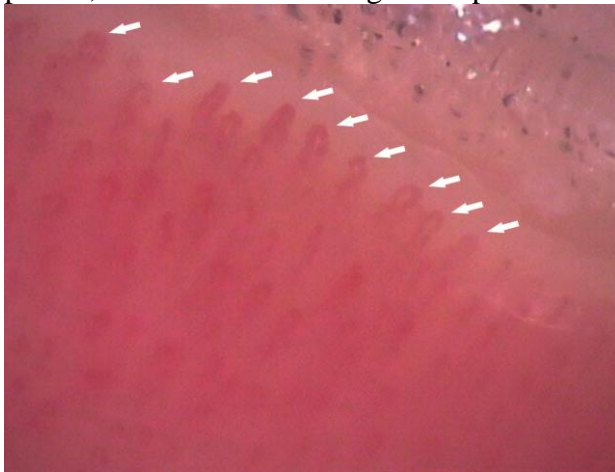


Fig. 16. Capillaroscopic pattern in RA with secondary RP, demonstrating presence of dilated capillaries (arrows), magnification 200x.

4. 2. Capillaroscopic pattern in psoriatic arthritis

In 30.2% (11/34) of the cases with PsA, RP was present. The mean capillary length in PsA patients ($0.166\pm 0.09\text{mm}$) was found to be significantly lower as compared with healthy individuals ($0.209\pm 0.07\text{mm}$), ($p<0.05$). The mean capillary density was significantly lower in PsA patients ($8\pm 1\text{capillaries/mm}$) as compared with healthy individuals ($10.2\pm 0.62\text{capillaries/mm}$), ($p<0.05$). In patients with PsA, capillaries with specific morphology - tight terminal convolutions were found in 58.8% (20/34) of the cases (Fig. 17). The finding is analogous to the vascular morphology in the psoriatic plaque. At Fig. 18 the capillary morphology of an active psoriatic plaque is demonstrated. The capillaries are visualized as terminal convolutions, while in the area of unaffected skin, adjacent to the psoriatic plaque their shape is like dot or comma (Fig. 19). Of note, tortuous blood vessels have been also observed at arthroscopic examination of the inflamed synovium of knee joint of PsA patients [45].

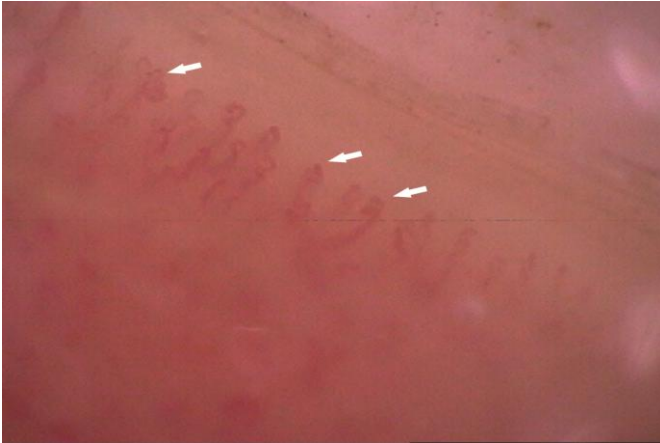

Fig. 17. Capillaroscopic pattern in PsA patient with involvement of hand joints, demonstrating tight terminal convolutions (arrows), magnification 200x.

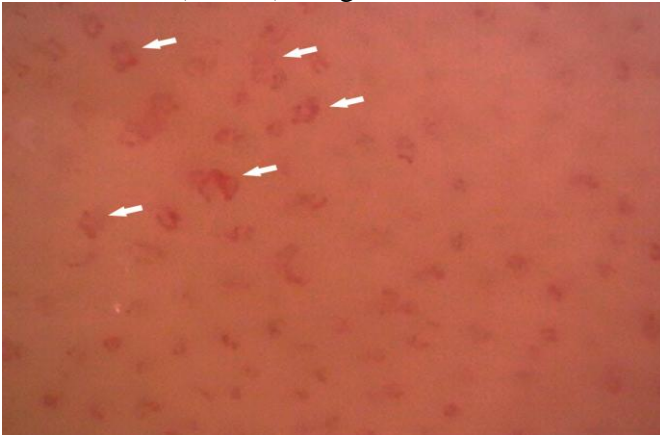


Fig. 18. Capillaroscopic picture of classic active, clinically evident psoriatic plaque, localized at the forearm, that demonstrates terminal convolution of the capillaries of the psoriatic plaque, magnification 200x (Videocap 3.0).

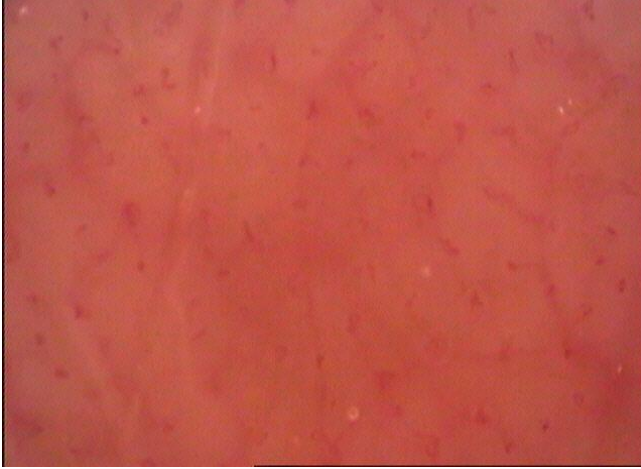

Fig. 19. Capillaroscopic picture of skin area, unaffected from psoriatic lesion, adjacent to the zone with psoriatic plaque, that is presented at Fig. 18. The picture demonstrates skin capillaries with normal morphology, that are visualized like dot or comma, magnification 200x (Videocap 3.0).

4. 3. Capillaroscopic pattern in early arthritis

We have found RP in 44% (4/9) of the examined patients with early symmetric arthritis, who were diagnosed as RA at the follow-up (7 patients with CCP-positive and RF-positive and 2 patients with seronegative RA). At the capillaroscopic examination, a normal capillaroscopic picture was observed in 66% (6/9) and

moderately dilated capillaries in 22.2% (2/9). A “scleroderma-like” pattern was found in 11.1% (1/9) of the patients with early arthritis, who presented with complaints of RP. The low frequency of the last type of capillaroscopic pattern in RA requires patients with such changes to be observed during the regular follow-up for the development of systemic rheumatic disease different from inflammatory arthritis.

5. Capillaroscopic pattern in other rheumatic diseases

5.1. Capillaroscopic pattern in primary Raynaud’s phenomenon

In 96.6% (30/31) of the patients with primary RP moderately dilated capillaries were observed. A normal capillaroscopic picture is one of the diagnostic criteria for primary RP. The mean capillary diameter of the arterial and the venous limb in patients with primary RP were found to be significantly wider as compared with healthy controls, which was easily detected by the software for quantitative assessment. The mean diameters of the arterial ($0.018\pm 0.004\text{mm}$) and the venous limb

($0.026\pm 0.006\text{mm}$) were significantly wider as compared with those of healthy volunteers ($0.012\pm 0.001\text{mm}$ for the arterial limb and 0.017 ± 0.002 for the venous limb), ($p<0.005$), (Fig. 20). The mean capillary density in primary RP (8.86 ± 1.10 capillaries/mm, range 7-11) was significantly lower than those in healthy volunteers (10.34 ± 0.59 capillaries/mm), ($p<0.005$). In one patient (3.2%) with primary RP with 51 years' history for vasospastic attacks, giant capillaries, haemorrhages and avascular areas were observed, but without clinical and laboratory signs for CTD. The finding is probably associated with microvascular abnormalities, that appear after the long duration of the processes of ischemia and reperfusion.

5. 2. Capillaroscopic pattern in primary fibromyalgia

RP was found in 65% (17/26) of patients with primary fibromyalgia. The most frequent finding in patients with primary fibromyalgia was the presence of moderately dilated capillaries in 85% (22/26) of cases, including patients with RP as well as patients without

peripheral vasospasm. The mean diameters of the arterial ($0.017\pm 0.004\text{mm}$) and the venous limb ($0.023\pm 0.004\text{ mm}$) in patients with primary fibromyalgia were significantly wider as compared with the respective values in healthy controls ($0.013\pm 0.001\text{mm}$ for the arterial limb and $0.018\pm 0.002\text{mm}$ for the venous limb), ($p<0.05$). The mean length of the capillary loop ($0.183\pm 0.054\text{mm}$) was significantly lower as compared with those in healthy controls ($0.199\pm 0.074\text{mm}$), ($p<0.05$). The mean capillary density in patients with primary fibromyalgia (9 ± 1.1 capillaries/mm; range 7-12) was found to be significantly lower as compared with those in healthy subjects (10 ± 0.59 capillaries/mm), ($p<0.05$). In the group of primary fibromyalgia, signs of microangiopathy (giant capillaries, haemorrhages, avascular areas and neoangiogenesis) characteristic of CTD were not found (Fig. 21).

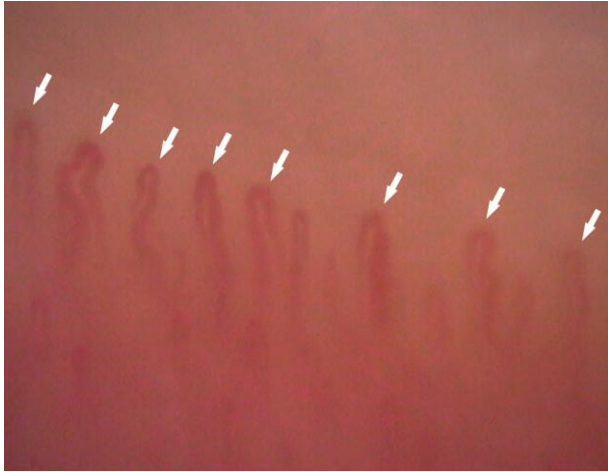


Fig. 20. Capillaroscopic pattern in primary RP, demonstrating moderately dilated capillaries (arrows), magnification 200x.

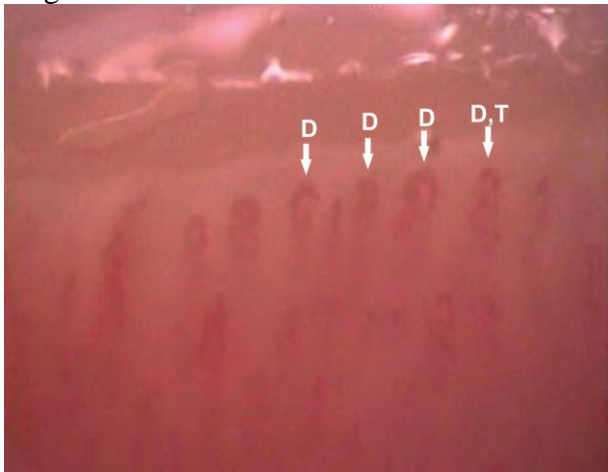


Fig. 21. Capillaroscopic pattern in primary fibromyalgia, demonstrating moderately dilated capillaries (D) and tortuous capillaries (T), magnification 200x.

5. 3. Capillaroscopic pattern in paraneoplastic Raynaud's phenomenon

As the capillaroscopic pattern in paraneoplastic RP is not studied specifically and is not well-defined, to elucidate this problem, three patients with paraneoplastic rheumatic conditions are reported here. They manifested with severe secondary RP (one male with scleroderma-like syndrome and two women with paraneoplastic DM). Cases are here presented with distinct emphasis on capillaroscopic findings.

Case 1

A 58-year-old male patient with 15 years' duration of psoriasis and PsA. The patient has been treated with methotrexate (15 mg weekly). In the last 5 years the patient reported about increasing severe digital ischemia with pallor, cyanosis, reactive hyperemia, pain and numbness during cold exposure. Skin thickening of the fingers had appeared during the last year. At clinical examination, acroosteolysis of some of the distal phalanges and sclerodactyly has been found without skin involvement proximal of the metacarpophalangeal joints, at the lower extremities, face or trunk (Fig. 22 and 23).

Computed tomography revealed a tumour in the middle lobe of the right lung with a diameter of 3 cm with metastases in the lymph nodes of the right hilus. The capillaroscopic examination revealed the classic “scleroderma” type pattern. Dilated and giant capillaries, single haemorrhages, slightly decreased mean capillary density, relatively preserved capillary distribution were observed. These features are specific for the “early” phase “scleroderma” type capillaroscopic pattern as mentioned above (Fig. 24).

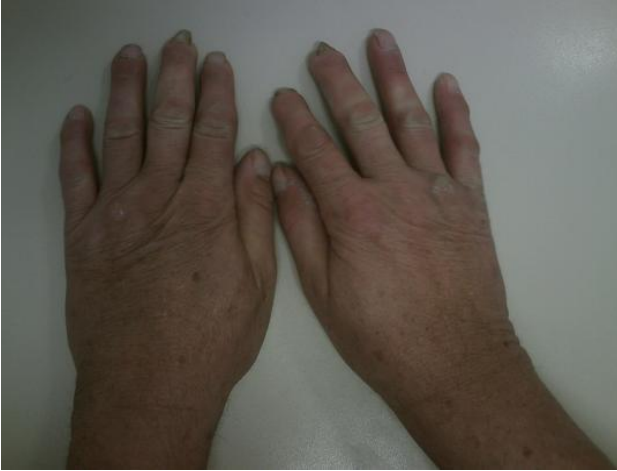

Fig. 22. 58-year-old man with psoriasis, PsA, severe RP. Acroosteolysis of the distal phalanges (the most profound of the 2nd and 3rd right fingers) and sclerodactyly are demonstrated.

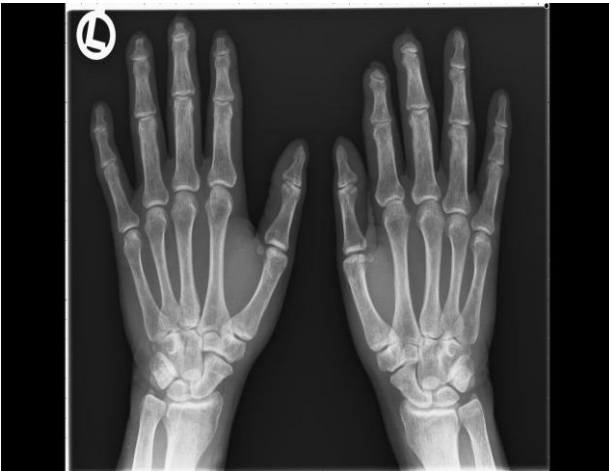

Fig. 23. Hand X-ray of the same patient, presented at Fig. 22. Acroosteolysis of the distal phalanges, the most profound of the 2nd and 3rd right fingers is demonstrated.

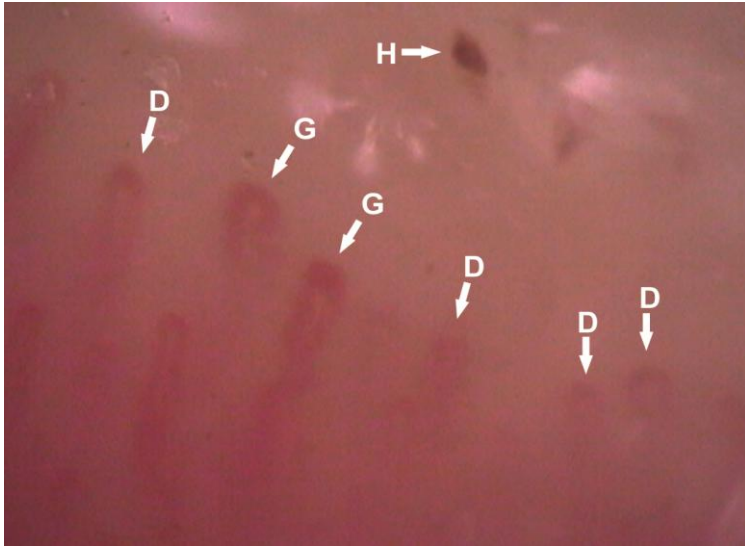


Fig. 24. An “early” phase “scleroderma” capillaroscopic pattern of the same patients, presented at Fig. 22 and 23. Presence of dilated (D), giant (G) capillaries, haemorrhage (H), relatively preserved capillary density and distribution are demonstrated, magnification 200x.

Case 2

A 48-year-old woman referred for consultation with a 5-month duration of proximal muscle weakness with abrupt onset, that progressed rapidly and confined the patient to the bed. The muscle weakness had appeared simultaneously with classic skin rash and severe RP. Chest computed tomography detected a round

formation in the right upper lobe and enlarged lymph nodes in the right hilus. The histological diagnosis of these lesions showed a differentiated papillar adenocarcinoma. The capillaroscopic examination showed frequent dilated and giant capillaries, haemorrhages and severe microvascular disarrangement - the so-called “scleroderma-like” pattern typical of the idiopathic forms of DM.

Case 3

A 56-year-old woman with a proven diagnosis of DM with secondary RP presented also in our outpatient clinic. One year later, a papillar carcinoma of the thyroid gland has been found and partial thyroidectomy was performed. The capillaroscopic examination revealed dilated and giant capillaries, elongated capillaries, decreased mean capillary density with avascular areas, severe microvascular disarrangement, single haemorrhages and a clear evidence for neoangiogenesis (Fig. 25). These capillaroscopic features characteristic of the “scleroderma-like” pattern in DM are indistinguishable from those in idiopathic DM as in the second case.

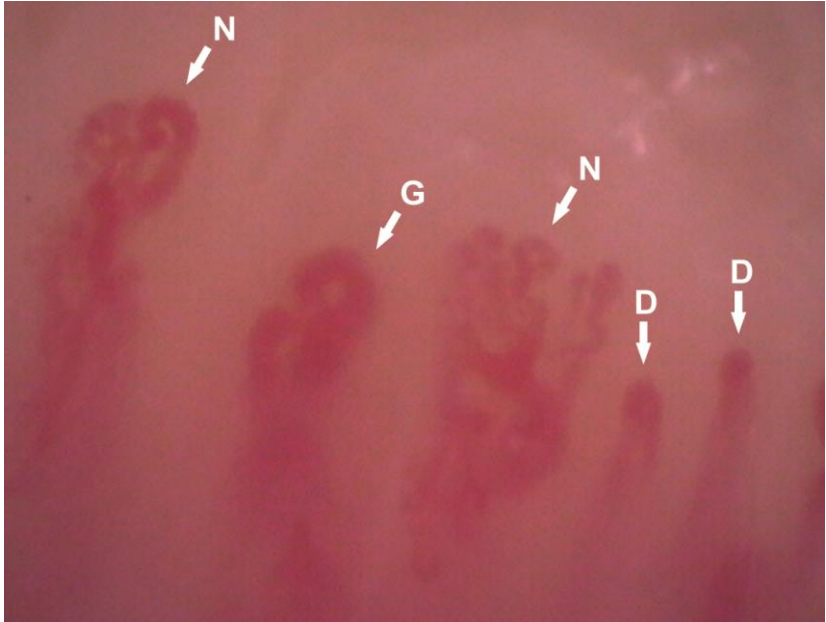


Fig. 25. Capillaroscopic pattern of 56-year-old woman with paraneoplastic DM associated with cancer of thyroid gland reveals dilated (D), giant (G) capillaries and neoangiogenesis (N); magnification 200x.

6. Capillaroscopic pattern in arterial hypertension

In untreated AH patients, a lower mean capillary density at the forearm, at the dorsum of the middle phalanx and in the nailfold area has been observed as compared with healthy controls [4]. The data about the respective values in AH patients, who receive

antihypertensive drugs are sparse. In the examined group of AH patients 49% (17/35) received antihypertensive treatment with ACE-inhibitors, 5.7% (2/35) with angiotensin receptor blocker, 62.8% (22/35) - β -blockers, 17 % (6/35) – calcium channel blockers, 25.7% (9/35) – diuretics and 2.8 % (1/35) – drug with a central nervous mechanism of action.

The mean capillary density of the nondominant hand of AH patients was 7.70 ± 0.97 capillaries/mm (range 6-9), which is significantly lower as compared with healthy volunteers (10.33 ± 0.56 capillaries/mm, range 9-12), ($p < 0.05$). The low mean capillary density was not associated with presence of avascular areas (Fig. 26). Signs of microangiopathy e. g., giant capillaries, haemorrhages, avascular areas and neoangiogenesis were not found in patients with AH.

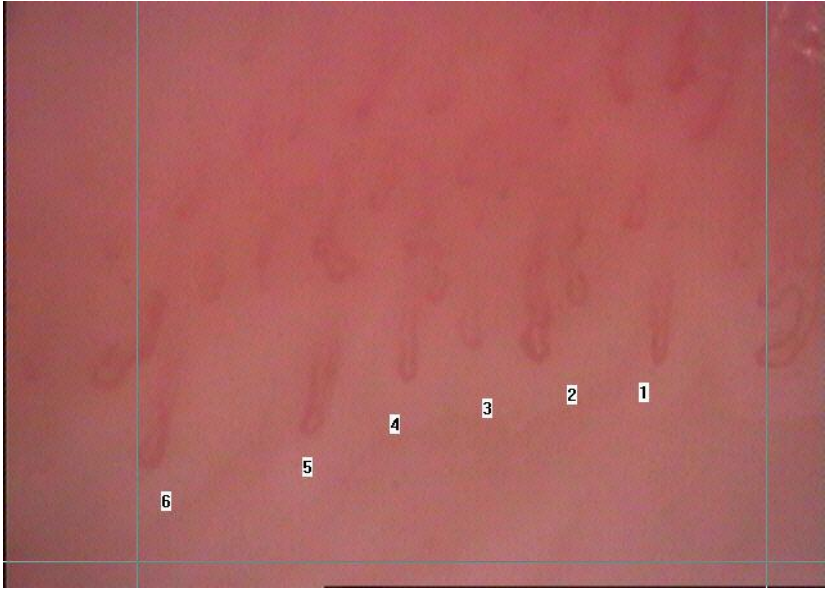


Fig. 26. Capillaroscopic pattern in patient with AH, demonstrating low mean capillary density per mm, but in each dermal papilla there is a capillary loop, without avascular areas, magnification 200x.

7. Comparison of qualitative and quantitative analysis of capillaroscopic images in patients with rheumatic diseases and evaluation the reproducibility of the qualitative assessment performed by two different investigators

The quantitative and qualitative analysis resulted in identical estimates in 74% (148/200) of the cases for

the detection of dilated capillaries, in 84% (168/200) for giant capillaries and in 91% (182/200) for the presence of avascular areas. The distribution of the equal estimates from the quantitative and qualitative analysis of the investigators, divided according to the diagnosis is presented in Table 6. In Table 7 the numbers of capillaroscopic images with presence and absence of dilated, giant capillaries and avascular areas, evaluated quantitatively and qualitatively respectively are shown. Using χ^2 test, the number of the images with presence and absence of a certain capillaroscopic parameter e. g., dilated, giant capillaries and avascular areas, evaluated quantitatively by investigator 1 and qualitatively by investigator 2, were compared. A statistically significant difference between the two methods for detection of dilated and giant capillaries was found ($p < 0.05$), but no significant difference regarding the detection of avascular areas ($p > 0.05$), (Table 7). The quantitative and qualitative methods were further compared for assessment of images with “scleroderma” and “scleroderma-like” type capillaroscopic pattern and from patients with primary RP. Among the analyzed images,

107 were from “scleroderma” and “scleroderma-like” type (73 from patients with SSc, 10 - from DM, 19 - UCTD and 5 patients with different form of overlap syndrome). 20 images were from patients with primary RP and showed the classic finding with presence of dilated capillaries, but without signs for microangiopathy. Results are presented in Table 8 and 9. Among the “scleroderma” and “scleroderma-like” images, we have again found a statistically significant difference between the quantitative and qualitative method for detection of dilated and giant capillaries ($p < 0.05$), while for the presence of avascular areas the difference was not significant ($p > 0.05$). Among the 20 capillaroscopic images from patients with primary RP, the estimates for absence of giant capillaries and avascular areas were equal in 100% ($p > 0.05$). For these group of capillaroscopic images, a statistically significant difference between the quantitative and the qualitative for the detection of dilated capillaries was not found ($p > 0.05$).

The qualitative assessment by two different investigators showed identical estimates as follows, 81%

(164/200) for the presence of dilated capillaries, 89% (177/200) for the detection of giant capillary loops, 85% (172/200) for the presence of avascular areas and in 100% (200/200) of the cases for the haemorrhages (Table 10). The distribution of the equal estimates, divided according to the diagnosis is presented in Table 10. Using χ^2 test, the number of the images with presence or absence of a certain capillaroscopic parameter e. g., dilated, giant capillaries, haemorrhages and avascular areas, evaluated qualitatively by both investigator 1 and 2, was compared. For the detection of dilated capillaries, a statistically significant difference between estimates of the two investigators was found ($p < 0.05$), while for giant capillaries, avascular areas and haemorrhages the difference was not statistically significant ($p > 0.05$). As the key capillaroscopic parameters for microangiopathy are giant capillaries, avascular areas, haemorrhages, their detection is of crucial importance for differentiation of primary RP from RP in the context of SSc and scleroderma-spectrum disorders. Thus, the non significant difference for qualitative detection of these capillaroscopic changes between two different

investigators demonstrates the high reproducibility of the qualitative assessment for detection of microvascular damage in rheumatic disease irrespective of the examiner. Here, we have to emphasize that haemorrhages were the most reliable parameter that is evaluated equally in 100% of the cases. Results are presented in Table 11. We have further evaluated the reproducibility of the qualitative assessment between two different investigators in the different type of capillaroscopic images for the 107 capillaroscopic images from “scleroderma” and “scleroderma-like” type and for the 20 images from primary RP. Results are presented in Table 12 and 13. Among the “scleroderma” and “scleroderma-like” images there were no significant difference between the estimates of the two investigators for all of the examined capillaroscopic changes e. g. dilated capillaries, giant capillaries, avascular areas, haemorrhages ($p>0.05$). Analogous results were achieved for the 20 capillaroscopic images from patients with primary RP that revealed 100% equal answers for absence of giant capillaries, avascular areas and haemorrhages. Regarding the detection of dilated

capillaries in these patients, no statistically significant difference between the estimates of the two investigators was found ($p>0.05$).

The results of the study have shown, that qualitative assessment of the capillaroscopic parameters in patients with rheumatic diseases, is an adequate method for the everyday rheumatologic practice especially in cases with primary RP for exclusion presence of microangiopathy. No significant difference between qualitative and quantitative methods of assessment was found for detection of avascular areas. However, the quantitative analysis is more precise especially for detection of capillary dilation.

A good reproducibility of the qualitative evaluation, performed by two different investigators was found. It supports the idea, that interpretation performed by different investigators, who are experienced with capillaroscopic images in the context of rheumatic disease, produces results that can be reliably compared in the daily practice.

Distribution of the capillaroscopic images according to the diagnosis	Capillaroscopic parameters	Dilated capillaries	Giant capillaries	Avascular areas
SSc, n=73 Early - 8 Active - 54 Late - 11		64/73 Early - 3/8 Active - 54/54 Late - 7/11	54/73 Early - 8/10 Active - 38/54 Late - 8/11	64/73 Early - 5/8 Active - 49/54 Late - 10/11
DM, n= 10 “scleroderma-like” pattern 10/10		10/10	8/10	8/10
UCTD and different forms of overlap associated with secondary RP, n=25 “scleroderma-like” pattern 21/25		21/25 “scleroderma-like” pattern 21/21	19/25 “scleroderma-like” pattern 14/21	22/25 “scleroderma-like” pattern 19/21
SLE, n=26		17/26	23/26	23/26
RA, n=46		29/46	44/46	45/46
Primary RP, n=20		7/20	20/20	20/20
Total number of equal estimates		148/200	168/200	182/200

Table 6. The distribution of the equal estimates from the quantitative and qualitative analysis of the investigators, divided according to the diagnosis.

Investigator 1 – quantitative/Investigator 2 – qualitative assessment Capillaroscopic parameters	Investigator 1 - quantitative assessment - number of images with presence or absence of a certain parameter	Investigator 2 - qualitative assessment- number of images with presence or absence of a certain parameter
Dilated capillaries $\chi^2 = 15.87, p < 0.05$	168 presence 32 absence	117 presence 83 absence
Giant capillaries $\chi^2 = 5.30, p < 0.05$	69 presence 131 absence	40 presence 160 absence
Avascular areas $\chi^2 = 0.210, p > 0.05$	65 presence 135 absence	59 presence 141 absence

Table. 7. Comparison of number of images with presence or absence of a certain capillaroscopic parameter evaluated by investigator 1 (quantitatively) and investigator 2 (qualitatively).

Investigator 1 – quantitative/Investigator 2 – qualitative assessment Capillaroscopic parameters	Investigator 1 - quantitative assessment - number of images with presence or absence of a certain parameter	Investigator 2 - qualitative assessment- number of images with presence or absence of a certain parameter
Dilated capillaries $\chi^2 = 7.49, p < 0.05$	107 presence 0 absence	93 presence 14 absence
Giant capillaries $\chi^2 = 6.33, p < 0.05$	64 presence 43 absence	38 presence 69 absence
Avascular areas $\chi^2 = 0.084, p > 0.05$	57 presence 50 absence	54 presence 53 absence

Table 8. Comparison of number of images from “scleroderma” and “scleroderma-like” capillaroscopic patterns with presence or absence of a certain capillaroscopic parameter, evaluated by investigator 1 (quantitatively) and investigator 2 (qualitatively).

Capillaroscopic parameters \ Investigator 1 – quantitative/Investigator 2 – qualitative assessment	Investigator 1 - quantitative assessment - number of images with presence or absence of a certain parameter	Investigator 2 - qualitative assessment- number of images with presence or absence of a certain parameter
Dilated capillaries $\chi^2 = 2.727, p > 0.05$	15 presence 5 absence	18 presence 2 absence
Giant capillaries $\chi^2 = 0, p > 0.05$	0 presence 20 absence	0 presence 20 absence
Avascular areas $\chi^2 = 0, p > 0.05$	0 presence 20 absence	0 presence 20 absence

Table 9. Comparison of number of capillaroscopic images of patients with primary RP with presence or absence of a certain capillaroscopic parameter, evaluated by investigator 1 (quantitatively) and investigator 2 (qualitatively).

Capillaroscopic Parameters Distribution of the capillaroscopic images according to the diagnosis	Dilated capillaries	Giant capillaries	Avascular areas	Haemorrhages
SSc, n=73 Early - 8 Active - 54 Late - 11	66/73 Early - 4/8 Active - 54/54 Late-8/11	59/73 Early- 4/8 Active - 45/54 Late - 10/11	61/73 Early - 5/8 Active - 46/54 Late - 10/11	73/73
DM, n=10 "scleroderma-like" pattern 10/10	10/10	8/10	6/10	10/10
UCTD and different forms of overlap associated with secondary RP, n=25 "scleroderma-like" pattern, n=19	21/25 "scleroderma-like" pattern, 19/19	20/25 "scleroderma-like" pattern, 15/19	22/25 "scleroderma-like" pattern, 19/19	25/25
SLE, n=26	20/26	24/26	19/26	26/26
RA, n=46	34/46	46/46	44/46	46/46
Primary RP, n=20	13/20	20/20	20/20	20/20
Total number of equal estimates	164/200	177/200	172/200	200/200

Table 10. The distribution of the equal estimates from the qualitative analysis of the two investigators, divided according to the diagnosis.

Investigator 1 and 2 – qualitative assessment Capillaroscopic parameters	Investigator 1 - qualitative assessment - number of images with presence or absence of a certain parameter	Investigator 2 - qualitative assessment- number of images with presence or absence of a certain parameter
Dilated capillaries $\chi^2 = 5.127, p < 0.05$	146 presence 52 absence	117 presence 83 absence
Giant capillaries $\chi^2 = 2.189, p > 0.05$	58 presence 142 absence	40 presence 160 absence
Avascular areas $\chi^2 = 0.223, p > 0.05$	53 presence 147 absence	59 presence 141 absence
Haemorrhages $\chi^2 = 0, p > 0.05$	40 presence 160 absence	40 presence 160 absence

Table. 11. Comparison of number of images with presence or absence of a certain capillaroscopic parameter, evaluated by both investigator 1 and 2 qualitatively.

Investigator 1 and 2 – qualitative assessment Capillaroscopic parameters	Investigator 1 - qualitative assessment - number of images with presence or absence of a certain parameter	Investigator 2 - qualitative assessment- number of images with presence or absence of a certain parameter
Dilated capillaries $\chi^2 = 3.032, p>0.05$	103 presence 4 absence	93 presence 14 absence
Giant capillaries $\chi^2 = 2.15, p>0.05$	53 presence 54 absence	38 presence 69 absence
Avascular areas $\chi^2 = 0.149, p>0.05$	50 presence 57 absence	54 presence 53 absence
Haemorrhages $\chi^2 = 0, p>0.05$	33 presence 74 absence	33 presence 74 absence

Table 12. Comparison of the number of images from “scleroderma” and “scleroderma-like” capillaroscopic pattern with presence or absence of a certain capillaroscopic parameter, evaluated by both investigator 1 and 2 qualitatively.

Investigator 1 and 2 – qualitative assessment Capillaroscopic parameters	Investigator 1 - qualitative assessment - number of images with presence or absence of a certain parameter	Investigator 2 - qualitative assessment- number of images with presence or absence of a certain parameter
Dilated capillaries $\chi^2 = 1.79, p > 0.05$	7 presence 13 absence	2 presence 18 absence
Giant capillaries $\chi^2 = 0, p > 0.05$	0 presence 20 absence	0 presence 20 absence
Avascular areas $\chi^2 = 0, p > 0.05$	0 presence 20 absence	0 presence 20 absence
Haemorrhages $\chi^2 = 0, p > 0.05$	0 presence 20 absence	0 presence 20 absence

Table 13. Comparison of the number of capillaroscopic images of patients with primary RP with presence and absence of a certain capillaroscopic parameter, evaluated by both investigator 1 and 2 qualitatively.

CHAPTER V

DISCUSSION

1. Systemic sclerosis

1. 1. Capillaroscopic pattern of the hands in SSc patients

The classic “scleroderma” type capillaroscopic pattern of the hands in SSc patients was observed in 97.2% (35/36) of the cases. This result is confirmatory and is similar to those, obtained by Maricq et al. (1980), who found a high frequency of capillaroscopic abnormalities in SSc in 83-93% of cases with overt SSc [90]. The frequency of the specific capillaroscopic pattern in SSc in the current study is higher than those of other investigators. Bergman et al. (2003) observed “scleroderma” type capillaroscopic picture in 70.4% of the examined SSc patients [14], Nagy et al. (2004) - in 87.5% of the patients with diffuse form of SSc and in 61.6% of the cases with limited form of the disease [101]. In the examined group of SSc patients in the present study an abnormal “scleroderma” type capillaroscopic pattern was observed in the hands in all but one female patient with limited SSc, who did not maintain the

obligatory period of 1 month without cutting her nailfolds and presented at the consultation with recent manicure. The data from the current study confirm the high frequency of the microvascular damage in SSc and the specific capillaroscopic findings at capillaroscopic examination of the nailfold area of the fingers in SSc patients.

In SSc patients with a duration of the disease less than 3 years, in 50% of the cases (5/10) an “early” phase “scleroderma” capillaroscopic pattern was found. In the other 50% (5/10) of the patients from this subgroup an „active“ phase „scleroderma“ type capillaroscopic pattern was observed. In this group of patients a “late” phase capillaroscopic changes were not found. In the group of SSc patients with duration of the disease > 3 years, a “late” phase capillaroscopic pattern was found, while the frequency of “early“ phase capillaroscopic pattern in this group was only 7.7% (2/26). These results also confirm that capillaroscopic changes in SSc differ in different phases of the disease, although the duration of the disease is not the only determinant factor for their development. The activity of the disease and the level of different

angiogenic and angiostatic factors play different and still not clearly defined role for dynamic of capillaroscopic changes in the different phases of SSc.

1.2. Association between capillaroscopic pattern and presence of digital ulcers in systemic sclerosis

It has been previously speculated that the development of ulcerations in SSc may be associated with the presence of avascular areas at the capillaroscopic examination [2]. A significant association between presence of digital ulcers and the lower number of capillaries in the distal row, as well as with higher number of megacapillaries and higher loop diameter was observed [120].

The results of the current study show that the presence of digital ulcers at the hands of SSc patients is strongly associated with an “active” phase “scleroderma” type capillaroscopic pattern of the finger with active digital ulcer. Such capillaroscopic changes were observed in all the patients with digital ulcers of the fingers (100%, 13/13). The observation of an “active” phase “scleroderma” type pattern in patients without digital

ulcers may therefore be used in the future as a predictor for the development of trophic changes, an indicator for modulation of vasoactive treatment for prevention of development of digital ulcers and as an additional objective method for evaluation of the disease activity score in SSc. An extensive observation with regular capillaroscopic examinations, 3-4 times per year may detect the dynamics in morphology of nailfold capillaries during the course of the disease, and the time frame between the appearance of an “active” phase capillaroscopic pattern and the development of digital ulcers.

1. 3. Capillaroscopic pattern of the toes in systemic sclerosis patients

Symptoms of RP of the feet were found in a high proportion of the examined SSc patients (94. 4%). These results are similar to those of La Montagna et al., who have found presence of RP in 90% of cases among the examined 100 SSc patients. Digital ulcers of the fingers were found in 36% (13/36) of cases and in 8.3% (3/36) in the toes. This percentage is lower than those of La

Montagna et al., who reported necrotizing RP with a frequency of 52% in the hands and 31% in the feet [76].

While the specific “scleroderma” type capillaroscopic pattern of the fingers of SSc patients facilitates the early diagnosis, the capillaroscopic pattern of the toes has not been studied in the current rheumatology. The results from the current study demonstrate that capillaroscopic pattern of the toes of SSc also shows the characteristic features of microangiopathy in 66.7% of the examined group. This frequency is significantly lower than those of hands (97.2%, $p < 0.05$). The abnormal “scleroderma” type capillaroscopic pattern was observed in the hands in all but one female patient with limited SSc, who did not maintain the obligatory period of 1 month without cutting her nailfolds and presented at the consultation with recent manicure. Capillaries in the distal row could not be visualized in this patient and the picture was hazy with traumatic haemorrhages. However, at the capillaroscopic examination of the toes of this patient, the classic “scleroderma” type capillaroscopic pattern was observed. Another clinical situation in SSc patients, in which

capillaroscopic examination of the fingers is impeded are severe contractures. Examination with a videocapillaroscope, designed as a microscope is here impossible. In contrast, it can be performed with devices, that are constructed with contact probe like those, which was used in the present study. In these difficult circumstances, capillaroscopic examination of the toes may offer an opportunity for assessment of microcirculation as it also reveals specific microvascular changes and thus possesses diagnostic potential although to a lower extent. The suggested use of nailfold capillaroscopy in patients with RP and suspected or established SSc is presented at Fig. 27.

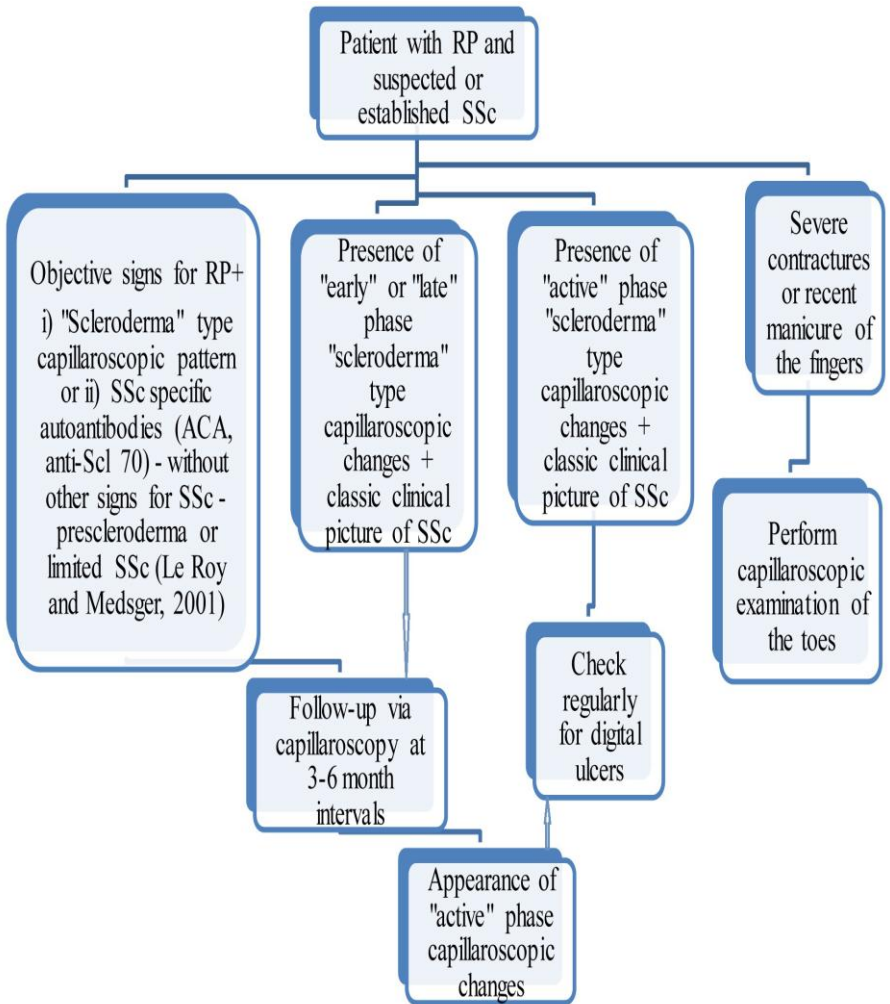


Fig. 27. Suggested use of nailfold capillaroscopy in patients with RP and suspected or established SSc.

2. Capillaroscopic pattern in systemic lupus erythematosus

The registered frequency of RP in the group of SLE patients was 73%, which is higher than those reported by the other authors in the current literature, varying from 10 to 45% [17,74].

The results from the study demonstrate that capillaroscopic examination is useful for the evaluation of microcirculation in SLE, especially those with secondary RP, but microvascular changes may be also observed in the absence of RP. In addition, a correlation between the abnormal capillaroscopic changes e. g. “SLE” and “scleroderma-like” type and the immunological activity of the disease was found.

The presence of “scleroderma-like” capillaroscopic pattern is associated in the current literature with the presence of anti-RNP antibody and overlap syndrome [47,56,67,81]. In the current study, such changes were found in 4 patients, all of whom demonstrated high immunologic activity, but without signs of overlap with other CTD. Anti-RNP antibody was

positive in 3 among the 4 patients with such capillaroscopic changes without signs for overlap syndrome. Active vasculitis of peripheral vessels was evident in 2 of them. Thus, it can be concluded that a “scleroderma-like” capillaroscopic pattern in SLE patients is not obligatory associated with overlap syndrome with other CTD. Such kind of capillaroscopic abnormalities may be observed in patients with active vasculitis of peripheral vessels as well as in patients with severe secondary RP and high immunologic activity.

3. Capillaroscopic pattern in undifferentiated connective tissue disease

RP is a characteristic feature of UCTD. In the current study, RP was found in 77% (24/31) of the patients from this group. A “scleroderma-like” pattern was observed in 38% (12/31) of cases, “nonspecific” capillaroscopic findings - in 51% (16/31) and normal capillaroscopic pattern - in 9.6% (3/31). Dynamic follow-up would reveal the predictive value of capillaroscopic pattern for the development of a distinct rheumatic disorder in patients with UCTD, particularly

scleroderma-spectrum disorder or SLE in patients with more profound microvascular changes, observed at capillaroscopic examination.

4. Capillaroscopic pattern in inflammatory arthritis

4. 1. Capillaroscopic pattern in rheumatoid arthritis

RP was found in 30.6% (19/62) of the patients with RA and in 3% (2/62) - a vasculitis of peripheral vessels was present. The results from the study show higher prevalence of RP in RA in comparison with the currently published literature data of other authors, who report varying, but significantly lower frequency from 2.7 to 17.2% [27,54,117].

The most frequent findings at nailfold capillaroscopic examination were prominent subpapillary plexus in 69% (40/62) and elongated capillaries in 58% (36/62). The diameters of the arterial and venous limb of the capillary loop were significantly wider in patients with RA and secondary RP as compared with RA patients without RP. On the other hand, dilated

capillaries were found not only in RA patients with RP (78.9%, 15/19), but also in RA patients without clinical symptoms of vasospasm of peripheral vessels (62.8%, 27/43). The diameters of the capillary loops in RA patients without secondary RP were also significantly wider than those of healthy controls, which may be associated with endothelial damage in different mechanisms in these patients in the context of the chronic inflammation. In 14.5% (9/62) of RA patients a “scleroderma-like” pattern was observed, 7 females and 2 males. Only in one of these cases an overlap of RA with SLE was found. A secondary RP and a secondary vasculitis were evident in this patient. In the rest patients with such capillaroscopic changes (8/9), no overlap with other CTD was found. In all the patients with “scleroderma-like” pattern (9/9), a secondary RP was present, and in 2/9 - a secondary vasculitis respectively. This suggests that “scleroderma-like” capillaroscopic pattern may be observed in RA patients although with low frequency and its presence is not obligatory associated with overlap syndromes. These findings are not reported by other authors in the current

rheumatologic literature.

4. 2. Capillaroscopic pattern in psoriatic arthritis

It is an interesting fact, that in the group of patients with PsA, RP was observed in 30.2% of the cases, which is a finding analogous to the frequency of RP in RA patients in the current study (30.6%). There are no available systemic studies in the current literature, that address the frequency of RP in PsA. The association between psoriasis, PsA and RP is reported as individual cases as well as the association of psoriasis and PsA with autoimmune disease like SSc, SLE, etc. [58,114].

In PsA patients, a significantly lower mean capillary length and mean capillary density was found as compared with healthy individuals. In patients with PsA, capillaries with specific morphology - tight terminal convolutions were present in a high proportion of the patients. This finding is analogous to the vascular morphology in the psoriatic plaque. The capillaroscopic examination of the uninvolved from psoriatic lesions skin, in the areas adjacent to the psoriatic plaques, showed normal capillary morphology. Interestingly, in contrast to

the increased vascularity in the psoriatic plaque and the synovium in PsA, in the area of the nailfold the mean capillary density was found to be significantly lower as compared with those in healthy individuals.

Of note, it has been found that vascular proliferation in the inflamed synovium in the knee joint of patients with PsA also is characterized with tortuous vessels, while the arthroscopic view of the inflamed synovium in RA reveals straight branching vessels. These specific vascular morphology in the psoriatic plaque, nailfold area and inflamed synovium in PsA is a hint for vascular pathology in this rheumatic entity [45]. In addition, the distinct differences between PsA and RA both at capillaroscopic examination and at arthroscopy are clues for pathogenetic differences between the two types of arthritis and possible distinct therapeutic approach in the future.

4. 3. Capillaroscopic pattern in early arthritis

The presence of RP in patients with early arthritis requires exclusion of SSc or SLE. In the group of patients with early arthritis, RP was present in 44% (4/9) of the

examined patients with early symmetric arthritis, who were diagnosed as RA at the follow-up. A “scleroderma-like” pattern was found in 11.1% (1/9) of patients with early arthritis, who presented with RP. The low frequency of this type of capillaroscopic pattern in RA requires patients with such changes to be observed during regular follow-up for the development of systemic rheumatic disease different from inflammatory arthritis.

In conclusion, in patients with early arthritis capillaroscopic examination is helpful for the differential diagnosis. The place of nailfold capillaroscopy in the management of patients with early arthritis and symptoms of RP is presented at Fig. 28.

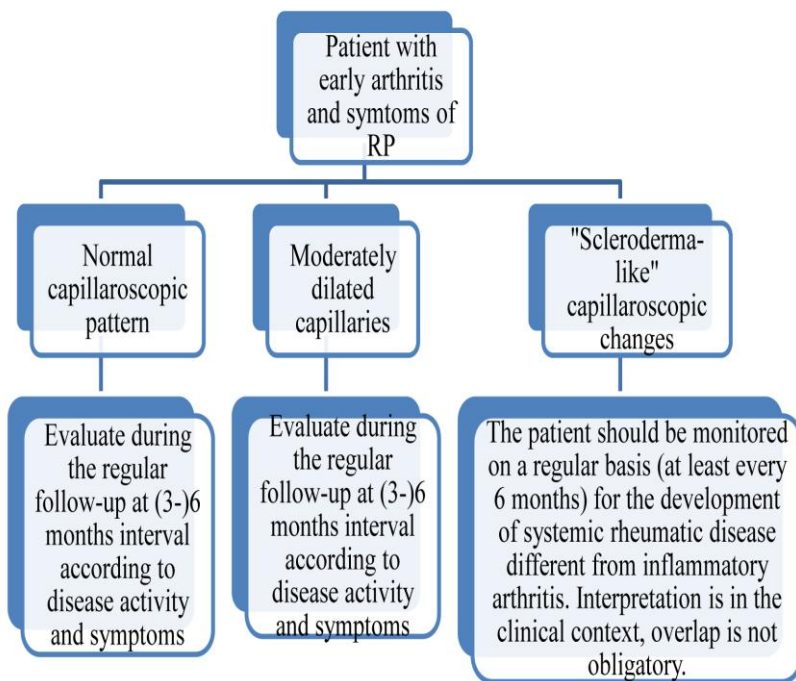


Fig. 28. The actual status of nailfold capillaroscopy in the management of patients with early arthritis and symptoms of RP.

5. Capillaroscopic pattern in other rheumatic diseases

5. 1. Capillaroscopic pattern in primary Raynaud's phenomenon

The absence of an abnormal capillaroscopic pattern is one of the diagnostic criteria for primary RP (Le Roy and Medsger) [79]. In the current study, a significantly wider mean capillary diameter of the arterial and the venous limb was found in almost all of primary RP patients (96.6%) as compared with healthy controls. These changes can be easily detected with the software programme for quantitative analysis. The capillary dilation, that is almost an obligatory finding in these patients, is probably a consequence of the recurrent processes of ischemia and reperfusion, that causes dysregulation of the vascular tone and permanent capillary dilation.

In one female patient with primary RP with 51 years' duration of vasospastic attacks, an abnormal capillaroscopic pattern (giant capillaries, haemorrhages and avascular areas) was observed with negative immunologic tests and no other signs for CTD. As a

possible explanation of this finding the long duration of ischemia and reperfusion and the subsequent microvascular injury may be considered. This finding leads to the conclusion, that interpretation of the capillaroscopic findings is only in the concrete clinical situation.

Of note, abnormal capillaroscopic pattern in patient with short duration of symptoms of RP or with late age of onset of the first symptoms should be strongly considered as a hint of systemic diseases.

The place of nailfold capillaroscopy in the management and follow-up of patients with signs of RP is presented at Fig. 29 and 30.

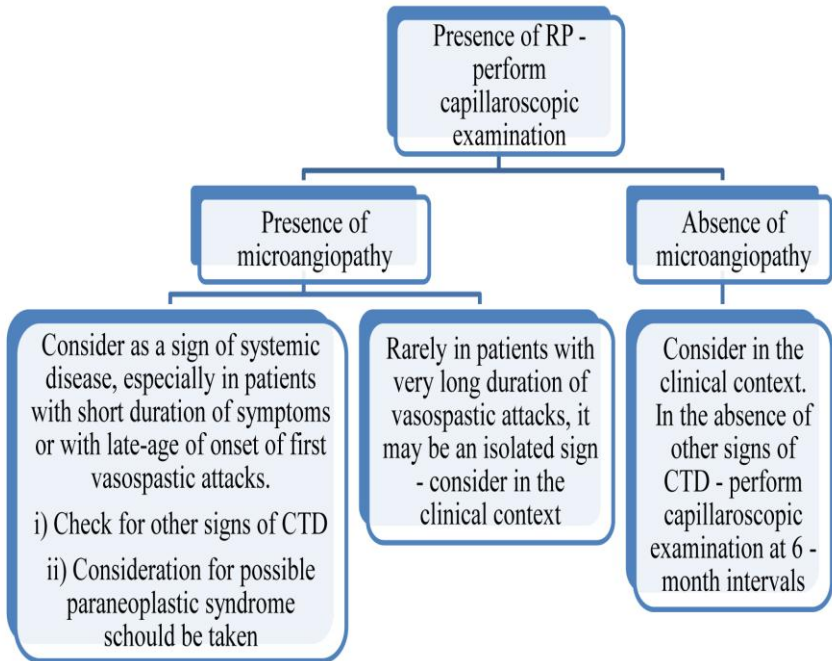


Fig. 29. The place of nailfold capillaroscopy in the management of patient with symptoms of RP.

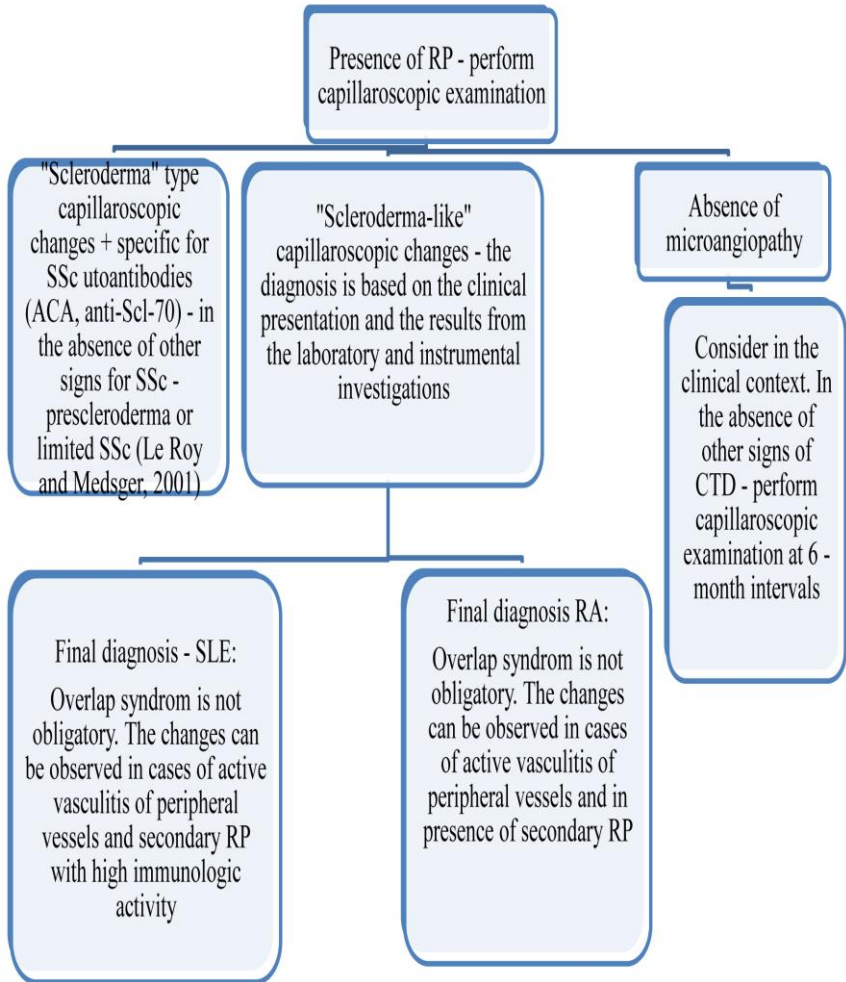


Fig. 30. The actual role of nailfold capillaroscopy in the management of patients with RP according to the observed capillaroscopic changes.

5. 2. Capillaroscopic pattern in primary fibromyalgia

The frequency of RP in primary fibromyalgia is significant, which suggests, that the capillaroscopic pattern in these clinical entity should be evaluated. In patients with primary fibromyalgia, significantly wider mean capillary diameters of the arterial and the venous limb were found as compared with healthy controls. These changes are similar to those observed in primary RP. The most frequent capillaroscopic finding in patients with primary fibromyalgia were moderately dilated capillaries in 85% (22/26) of the cases, that were found both in patients with and without symptoms of peripheral vasospasm. Capillaroscopic signs of microangiopathy characteristic of CTD were not observed in patients with primary fibromyalgia.

The capillaroscopic findings in primary fibromyalgia are analogous to those in primary RP. In the pathophysiology of fibromyalgia, the combination of interactions among external stressors, behavioral constructs, neurotransmitters, hormones, immune and sympathetic nervous system seems to be involved.

Sympathetic dysfunction could explain the main features of fibromyalgia, such as sleep disorders, anxiety, RP or pseudo-RP, sicca syndrome, and intestinal irritability [43] as well as the respective changes in the capillaroscopic picture. Interestingly, the characteristic capillaroscopic changes for primary fibromyalgia, that are moderately dilated capillaries, may be observed both in patients with and without RP. The dysfunction of sympathetic nervous system, that causes dysregulation of vascular tone is a possible explanation of this finding. It probably produces the symptoms of RP in a high proportion of patients with primary fibromyalgia. In the cases without classic history of vasospastic attacks probably the sympathetic dysfunction cause processes of pseudo-RP with intermittent, but recurrent dysregulation of vascular tone, that results in a permanent moderate capillary dilation in these patients.

5. 3. Capillaroscopic pattern in paraneoplastic Raynaud's phenomenon

Analysis of the capillaroscopic pattern in the

presented cases with paraneoplastic RP illustrates clearly the problem that capillaroscopic patterns in paraneoplastic RP in the context of scleroderma-like syndrome and DM appear to be indistinguishable from the microvascular changes in the respective idiopathic rheumatic diseases. It is well-known that late age at onset of RP is often in the context of systemic disease, that might also be a neoplastic process. If the suspicion for neoplastic condition is high, the patient should be screened as in every other routine case with paraneoplastic condition. Here, the capillaroscopic examination can not contribute to the differential diagnosis as the capillaroscopic features of microangiopathy are morphological and do not differ irrespective of the different starting causative factors in paraneoplastic and idiopathic systemic rheumatic diseases.

6. Capillaroscopic pattern in arterial hypertension

In AH patients, who receive antihypertensive drugs, the mean capillary density was found to be

significantly lower as compared with healthy volunteers. The low mean capillary density was not associated with presence of avascular areas, which confirms that reduced capillary density in these patients is structural and precedes the development of AH. Signs of microangiopathy e. g., giant capillaries, haemorrhages, avascular areas and neoangiogenesis, which are characteristic of CTD, were not found in patients with AH.

7. Comparison of qualitative and quantitative analysis of the capillaroscopic images in patients with rheumatic diseases and assessment of the reproducibility of the qualitative evaluation of the capillaroscopic parameters, performed by two different investigators

The qualitative analysis is more simple, accessible and fast for everyday application. The results from the study have shown, that qualitative assessment of the capillaroscopic parameters in patients with rheumatic diseases is an adequate method for the everyday rheumatologic practice, especially in cases with primary

RP for exclusion presence of microangiopathy. However, the quantitative analysis is more precise especially for detection of capillary dilation.

Results from the study demonstrate a good reproducibility of the qualitative evaluation, when performed by two different investigators. They suggest that interpretation, performed by different investigators, who are experienced with capillaroscopic images in the context of rheumatic disease, produces results that can be reliably compared in the daily practice.

8. Conclusions and original contributions

8. 1. This is the first study addressing the capillaroscopic patterns of the toes of patients with SSc. Although better protected from exposure to low temperatures, toes are affected from vasospastic attacks in the majority of patients. The capillaroscopic examination of the toes also reveals the specific for SSc “scleroderma” type capillaroscopic changes, but their frequency is significantly lower as compared with those of the fingers, which is probably also related to less severe RP and to a lower skin score in the feet. Therefore, the results from the study not only illustrate the systemic vascular pathophysiology of SSc, but also reveal the distinct differences of “similarly” affected vessels in different parts of the body. With respect to the clinical practice, examination of the toes could be considered to be added to the algorithm of a capillaroscopic evaluation of microcirculation in these patients, especially when SSc is suspected, but capillaroscopic examination of the fingers is hampered by different factors.

8. 2. An association between an “active” phase

“scleroderma” type pattern and the presence of digital ulcers of the hands of SSc patients was observed. This finding suggests a prognostic potential of this type of pattern to predict development of trophic changes, to serve as an indicator for modulation of vasoactive treatment and as an additional objective method for evaluation of the disease activity score in SSc.

8. 3. In SLE patients, it has been found that capillaroscopic examination reveals microvascular changes also in the absence of RP.

Here, the results from the study illustrate the correlation between capillaroscopic changes and immunological profile.

Although the presence of a “scleroderma-like” capillaroscopic pattern is associated in the current literature with the presence of anti-RNP antibody and overlap syndrome, in the present study such changes were found in 4 patients, all of whom demonstrated high immunologic activity, but without signs for overlap with other CTD. These changes were found in the context of active vasculitis of peripheral vessels and in cases with secondary RP with high immunologic activity. Thus, it

could be concluded that the “scleroderma-like” capillaroscopic pattern in SLE patients is not obligatory associated with an overlap syndrome with other CTD.

8. 4. This is the first extensive study of capillaroscopic pattern in RA with and without RP. Nailfold capillaroscopy revealed characteristic changes in patients with RA both with and without RP. Dilated capillaries are observed both in patients with and without RP. Presence of capillary dilation in the absence of vasospastic attacks is associated with endothelial damage that develops in different mechanisms in the context of chronic systemic inflammation.

For the first time in the literature it is reported, that “scleroderma-like” capillaroscopic pattern may be observed in RA patients although with low frequency, and these microvascular changes are also not obligatory associated with overlap syndrome with other CTD.

8. 5. This is the first extensive study for evaluation the role of the capillaroscopy in patients with other inflammatory arthritis e.g., PsA and early arthritis. Nailfold capillaroscopy revealed characteristic changes in the RA-like form of PsA and in the subtype of the disease

with involvement of the distal interphalangeal joints.

In patients with early arthritis, the capillaroscopic examination may facilitate differential diagnosis.

Results from the present study confirm the necessity for inclusion the nailfold capillaroscopy in the diagnostic algorithm in patients with inflammatory arthritis.

8. 6. Capillaroscopic pattern in cases of paraneoplastic RP was reported and it was demonstrated that in paraneoplastic scleroderma-like syndrome and DM capillaroscopic changes are analogous to those in the idiopathic forms of the diseases. The capillary changes are morphological and although caused by different factors in idiopathic and paraneoplastic rheumatic conditions, they do not differ.

8. 7. New insights about capillaroscopic pattern in primary RP are given in the current dissertation. It has been demonstrated that a nonsignificant dilation of capillary loops detected by the software for quantitative assessment is almost an obligatory finding in patients with primary RP. On the other hand, in patients with long duration of primary RP, an abnormal capillaroscopic

pattern (giant capillaries, haemorrhages and avascular areas) may be observed without other signs for CTD.

8. 8. New insights about capillaroscopic pattern in primary fibromyalgia are given in the dissertation. It has been concluded, that moderate capillary dilation may be observed in these patients in the context of dysregulated vascular tone due to sympathetic nervous system dysfunction. Of note, these changes are observed both in patients with symptoms of RP as well as in those without history for classic RP, that is probably related to pseudo-RP process at the level of small blood vessels in the context of sympathetic dysregulation. These capillaroscopic changes are analogous to those in primary RP. No signs of microangiopathy were found in primary fibromyalgia patients.

8. 9. The analysis of capillaroscopic pattern in patients with AH, who receive antihypertensive treatment, showed that the mean capillary density is significantly lower as compared with healthy individuals, but these findings are not associated with presence of avascular areas or other major signs of microangiopathy. Capillaroscopic changes are morphological and the

antihypertensive treatment does not influence them.

8. 10. In the current study, it has been demonstrated, that the qualitative assessment of capillaroscopic parameters in patients with rheumatic diseases is a reliable method for the everyday rheumatologic practice especially in cases with primary RP to exclude presence of microangiopathy. However, the quantitative analysis is more precise especially for detection of capillary dilation.

Results from the present study demonstrate also a good reproducibility of the qualitative evaluation, performed by two different investigators.

8. 11. The results from the dissertation will facilitate the establishment of the capillaroscopic examination in unclear clinical situations of the rheumatologic practice.

CHAPTER VI

SUMMARY

Nailfold capillaroscopic examination is a noninvasive technique with a substantial potential for the evaluation of the acral microcirculation in vivo. In addition, it is the only available technique for an on-demand analysis of the nutritional capillaries. At present, the main indication for capillaroscopic examination in rheumatology is the presence of RP. The method is currently applied for differentiation of primary RP from RP in the context of SSc and other scleroderma-spectrum-disorders. However, the sparse knowledge about specific capillaroscopic patterns in other rheumatic diseases and the absence of guidelines for analysis of capillaroscopic images are still limiting factors for application of nailfold capillaroscopy in the everyday practice when diagnosing rheumatologic patients

Therefore, this thesis addresses novel aspects of the application of nailfold capillaroscopy in rheumatology.

Chapter 1 provides an overview of the current application of nailfold capillaroscopy and includes the analysis of the actuality of the subject. **Chapter 2** addresses the aim and tasks of the dissertation and **Chapter 3** presents the materials and methods included in the dissertation. The study includes 297 patients with rheumatic diseases, who were examined during routine in- and outpatient consultation at the Chair for Internal Medicine and Rheumatology in the Justus-Liebig-University Giessen, Department of Rheumatology and Clinical Immunology, Kerckhoff Clinic, Bad Nauheim. The investigated patient groups consisted of 36 SSc patients, 30 SLE patients, 31 patients with UCTD, 62 RA

patients, 9 patients with early arthritis, 34 patients with PsA with a RA-like form and with a subtype of the disease with involvement of the distal interphalangeal joints, 31 patients with primary RP, 26 patients with primary fibromyalgia, 3 patients with paraneoplastic RP, 35 patients with essential mild-to-moderate AH without systemic rheumatic disease and control group with 42 healthy volunteers without known disease, who did not receive medications. Nailfold capillaroscopy was performed with a commercially high-end videocapillaroscope (Videocap 3.0, DS Medica, Italy). The findings were analysed qualitatively and quantitatively and were compared with clinical, laboratory and immunological data of the patients.

Based on the results of the examinations of the thesis, the following novel contributions have been

achieved: analysis and characterization of the capillaroscopic pattern of the toes of SSc patient, capillaroscopic pattern in the primary fibromyalgia, RA with and without RP, early undifferentiated arthritis, paraneoplastic RP, AH patients, who receive antihypertensive therapy. In addition, the qualitative and quantitative methods for evaluation of capillaroscopic images have been evaluated (**Chapters 4 and 5**).

In conclusion, it could be demonstrated that nailfold capillaroscopy is a method that provides valuable and valid information in several common rheumatic diseases with and without symptoms of peripheral vasospasm. Therefore, the results from the dissertation will contribute to the establishment of capillaroscopic analysis in hitherto uncharacterized clinical situations in the rheumatologic practice.

ZUSAMMENFASSUNG

Die Nagelfalz-Kapillarmikroskopie ist eine nichtinvasiv und mit wenig Zeitaufwand durchführbare Untersuchung zur Analyse der akralen Mikrozirkulation. Derzeit liegt das Haupteinsatzgebiet der Kapillarmikroskopie in der Differenzialdiagnose unklarer Durchblutungsstörungen bei entzündlich-rheumatischen und immunologischen Krankheitsbildern, vor allem bei prominentem Raynaud Phänomen. Hier wird die Kapillaroskopie in der Routineversorgung für die Differenzierung der primären und sekundären Formen des Raynaud Phänomens und zur Diagnosestellung bei systemischer Sklerose und Sklerodermie-ähnlichen Erkrankungen verwendet. Trotz der guten Verfügbarkeit der Kapillaroskopie gibt es nur wenige Erkenntnisse für kapillarmikroskopische Muster bei anderen

rheumatischen Erkrankungen und mit akralen Ischämien assoziierten Entitäten. In der vorliegenden
Dissertationsarbeit wurden daher die Nagelfalz-
Kapillarmikroskopie Muster bei verschiedenen
rheumatischen Erkrankungen im Detail analysiert.

Kapitel 1 beinhaltet die Einführung und den Überblick über die aktuelle Verwendung der Kapillarmikroskopie in die Rheumatologie und die Einbindung in den aktuellen Stand des Wissens.

Kapitel 2 legt die Ziele und die Aufgabenstellung der Dissertation dar, **Kapitel 3** beschreibt die Patienten und Methodik. Die Studie umfasste 297 Patienten mit verschiedenen rheumatischen Erkrankungen, die am Lehrstuhl für Innere Medizin der Justus-Liebig Universität Giessen in der Abteilung für Rheumatologie und Klinische Immunologie, Kerckhoff Klinik, Bad

Nauheim untersucht wird: 36 Patienten mit systemischer Sklerose, 30 mit systemischen Lupus erythematoses, 31 mit undifferenzierten Kollagenose, 62 mit rheumatoide Arthritis, 9 mit Früharthritis, 34 Patienten mit Psoriasisarthritis und peripherer Beteiligung, 3 mit paraneoplastischen Raynaud Syndrom, 31 Patienten mit primäres Raynaud Phänomen, 26 Patienten mit primäre fibromyalgie, 35 Patienten mit primäre arterieller Hypertonie ohne systemische rheumatische Erkrankungen (antihypertensiv behandelt) und 42 gesunde Kontrollen. Die Nagelfalz-Kapillarmikroskopie wurde mit einem high-end Videokapillaroskop (Videocap 3.0, DS Medica, Italien) durchgeführt. Die kapillarmikroskopischen Befunde werden quantitativ und qualitativ analysiert und mit klinischen und Laborbefunden verglichen.

(Kapitel 4 und 5). Die Analyse der Daten zeigte, dass die Nagelfalzkapillaroskopie eine wertvolle diagnostische Methode in der Differenzialdiagnostik von verschiedenen rheumatischen Erkrankungen mit und ohne akrale Minderperfusion darstellt. Die Ergebnisse dieser Dissertation sollen auch mithelfen, die Frühdiagnostik rheumatischer Erkrankungen zukünftig zu verbessern und praxisnäher zu gestalten

CHAPTER VII

REFERENCES

1. Aguiar T, Furtado E, Dorigo D, Bottino D. Nailfold videocapillaroscopy in primary Sjögren's syndrome. *Angiology*. 2006;57(5):593-9.
2. Alivernini S, De Santis M, Tolusso B, Mannocci A, Bosello SL, Peluso G et al. Skin ulcers in systemic sclerosis: determinants of presence and predictive factors of healing. *J Am Acad Dermatol*. 2009;60(3):426-35.
3. Anders HJ, Sigl T, Schattenkirchner M. Differentiation between primary and secondary Raynaud's phenomenon: a prospective study comparing nailfold capillaroscopy using an ophthalmoscope or stereomicroscope. *Ann Rheum Dis*. 2001;60:407-409.
4. Anderson ME, Allen PD, Moore T, Hillier V, Taylor CJ, Herrick AL. Computerized nailfold videocapillaroscopy – a new tool for assessment of Raynaud's phenomenon. *J Rheumatol*. 2005;32:841-8.
5. Antonios TFT, Singer RJ, Markandu ND, Mortimer PS, MacGregor GA. Structural skin capillary rarefaction in essential hypertension. *Hypertension*. 1999;33:998-1001.

6. Antonios TFT, Singer RJ, Markandu ND, Mortimer PS, MacGregor GA. Rarefaction of skin capillaries in borderline essential hypertension suggest an early structural abnormality. *Hypertension*. 1999;34:655-8.
7. Antonios TFT, Rattray FM, Singer RJ, Markandu ND, Mortimer PS, MacGregor GA. Rarefaction of skin capillaries in normotensive offspring of individuals with essential hypertension. *Heart*. 2003;89:175-8.
8. Arnett FC, Edworthy SM, Bloch DA, McShane DJ, Fries JF, Cooper NS et al. The American Rheumatism Association 1987 revised criteria for the classification of rheumatoid arthritis. *Arthritis Rheum*. 1988;31:315-24.
9. Asherson RA, Pierangeli SS, Cervera R. Is there a microangiopathic antiphospholipid syndrome? *Ann Rheum Dis*. 2007;66:429–32.
10. Barker DJ, Bull AR, Osmond C, Simmonds SJ. Fetal and placental size and risk of hypertension in adult life. *Br Med J*. 1990;301:259–62.
11. Belch JFF. Raynaud's phenomenon: its relevance to scleroderma. *Ann Rheum Dis*. 1991;50:839-45.
12. Beltran E, Toll A, Pros A, Carbonell J, Pujol RM. Assessment of nailfold capillaroscopy by x30 digital

epiluminiscence (dermoscopy) in patients with Raynaud's phenomenon. *Clin Lab Invest.* 2007;156:892-8.

13. Benedek TG. Neoplastic associations of rheumatic diseases and rheumatic manifestations of cancer. *Clin Geriatr Med.* 1988;4(2):333-55.

14. Bergman R, Sharony L, Schapira D, Nahir MA, Balbir-Gurman A. The handheld dermatoscope as a nail-fold capillaroscopic instrument. *Arch Dermatol.* 2003;139:1027-30.

15. Bernatsky S, Ramsey-Goldman R, Clarke A. Malignancy and autoimmunity. *Curr Opin Rheumatol.* 2006;18:129-34.

16. Bhushan M, Moore T, Herrick AL, Griffiths CE. Nailfold video capillaroscopy in psoriasis. *Br J Dermatol.* 2000;142:1171-6.

17. Block JA, Sequeira W. Raynaud's phenomenon. *Seminars Lancet*, 357, 2001, 2042-8.

18. Blockmans D, Beyens G, Verhaeghe R. Predictive value of nailfold capillaroscopy in the diagnosis of connective tissue diseases. *Clin Rheumatol.* 1996; 15(2):148-53.

19. Bollinger A, Fagrell B, Clinical capillaroscopy - a guide to its use in clinical research and practice. Hogrefe & Huber Publishers Toronto 1990: pp. 1-123.
20. Bongard O, Bounameaux H, Miescher PA, De Moerloose P. Association of anticardiolipin antibodies and abnormal nailfold capillaroscopy in patients with systemic lupus erythematosus. *Lupus*. 1995;4(2):142-4.
21. Braverman IM. The cutaneous microcirculation. *J Investig Dermatol Symp Proc*. 2000;5(1):3-9.
22. Bredemeier M, Xavier RM, Capobianco KG, Restelli VG, Rohde LE, Pinotti AF et al. Nailfold capillary microscopy can suggest pulmonary disease activity in systemic sclerosis. *J Rheumatol*. 2004;31:286-94.
23. Bukhari M, Hollis S, Moore T, Jayson MI, Herrick AL. Quantitation of microcirculatory abnormalities in patients with primary Raynaud's phenomenon and systemic sclerosis by videocapillaroscopy. *Rheumatology (Oxford)*. 2000;39(5):506-12.
24. Capobianco KG, Xavier RM, Bredemeier M, Restelli VG, Brenol JC. Nailfold capillaroscopic findings in primary Sjögren's syndrome: clinical and serological correlations. *Clin Exp Rheumatol*. 2005;23(6):789-94.

25. Caramaschi P, Volpe A, Canestrini S, Bambara LM, Faccini G, Carletto A, Biasi D. Correlation between homocysteine plasma levels and nailfold videocapillaroscopic patterns in systemic sclerosis. *Clin Rheumatol.* 2007;26:902–907
26. Caramaschi P, Canestrini S, Marinelli N, Volpe A, Pieropan S, Ferrari M et al. Scleroderma patients nailfold videocapillaroscopic patterns are associated with disease subset and disease severity. *Rheumatology (Oxford).* 2007;46(10):1566-9.
27. Carrol GJ, Withers K, Bayliss CE. The prevalence of Raynaud's syndrome in rheumatoid arthritis. *Ann Rheum Dis.* 1981;40:567-70.
28. Chang CH, Tsai RK, Wu WC, Kuo SL, Yu HS. Use of dynamic capillaroscopy for studying cutaneous microcirculation in patients with diabetes mellitus. *Microvasc Res.* 1997;53(2):121-7
29. Ciołkiewicz M, Domysławska I, Ciołkiewicz A, Klimiuk PA, Kuryliszyn-Moskal A. Coexistence of systemic sclerosis, scleroderma-like syndromes and neoplastic diseases. *Pol Arch Med Wewn.* 2008; 118(3):119-26.

30. Clements P, Lachenbruch P, Siebold J, White B, Weiner S, Martin R et al. Inter and intraobserver variability of total skin thickness score (modified Rodnan TSS) in systemic sclerosis. *J Rheumatol.* 1995; 22(7):1281–5.
31. Cony M, Klene-Boudard C, Fontan I, Sanciaume C, Sanciaume C, Sarrat P, Taieb A, Maleville J. Periungual capillaroscopy patterns in normal children. *Arch Fr Pediatr.* 1992;49(3):171-4.
32. Combe B, Landewe R, Lukas C, Bolosiu HD, Breedveld F, Dougados M et al. EULAR recommendations for the management of early arthritis: report of a task force of the European Standing Committee for International Clinical Studies Including Therapeutics (ESCISIT), *Ann Rheum Dis.* 2007;66:34-45.
33. Cortes S, Cutolo M. Capillaroscopic patterns in rheumatic diseases. *Acta Reum Port.* 2007;32:29-36.
34. Cutolo M, Grassi W, Matucci Cerinic M. Raynaud's phenomenon and the role of capillaroscopy. *Arthritis Rheum.* 2003;48(11):3023-30.
35. Cutolo M, Sulli A, Pizzorni C, Accardo S. Nailfold

videocapillaroscopy assessment of microvascular damage in systemic sclerosis, *J Rheumatol*. 2000;27:155-60.

36. Cutolo M, Pizzorni C, Tuccio M, Burroni A, Craviotto C, Basso M et al. Nailfold videocapillaroscopic patterns and serum autoantibodies in systemic sclerosis. *Rheumatology (Oxford)*. 2004;43:719-26.

37. Cutolo M, Pizzorni C, Sulli A. Capillaroscopy. *Best Pract Res Clin Rheumatol*. 2005; 19(3): 437–52.

38. Cutolo M, Sulli A, Secchi ME, Olivieri M, Pizzorni C. The contribution of capillaroscopy to the differential diagnosis of connective autoimmune diseases. *Best Pract Res Clin Rheumatol*. 2007;21(6): 1093–108.

39. Cutolo M, Sulli A, Secchi ME, Paolino S, Pizzorni C. Nailfold capillaroscopy is useful for the diagnosis and follow-up of autoimmune rheumatic diseases. A future tool for the analysis of microvascular heart involvement? *Rheumatology (Oxford)*. 2006;45:43-6.

40. Dancour MA, Vaz JL, Bottino DA, Bouskela E. Nailfold videocapillaroscopy in patients with systemic lupus erythematosus. *Rheumatol Int*. 2006;26(7):633-7.

41. de Holanda Mafaldo Diógenes A, Bonfã E, Fuller R, Correia Caleiro MT. Capillaroscopy is a dynamic process

- in mixed connective tissue disease. *Lupus*. 2007; 16(4):254-8.
42. De Angelis R, Grassi W, Cutolo M. A growing need for capillaroscopy in rheumatology. *Arthritis Rheum*. 2009;61(3):405-10.
43. Di Franco M, Iannuccelli C, Valesini G. Neuroendocrine immunology of fibromyalgia. *Ann N Y Acad Sci*. 2010;1193:84-90.
44. Dolezalova P, Young SP, Bacon PA, Southwood TR. Nailfold capillary microscopy in healthy children and in childhood rheumatic diseases: a prospective single blind observational study. *Ann Rheum Dis*. 2003; 62(5):444-9.
45. Fiocco U, Cozzi L, Chieco-Bianchi F, Rigon C, Vezzù M, Favero E et al. Vascular changes in psoriatic knee joint synovitis *J Rheumatol*. 2001; 28(11):2480-6.
46. Frödin T, Bengtsson A, Skogh M. Nailfold capillaroscopy findings in patients with primary fibromyalgia. *Clin Rheumatol*. 1988;7(3):384-8.
47. Furtado RNV, Pucinell MLC, Cristo VV, Andrade LEC, Sato EI. Scleroderma-like nailfold capillaroscopic abnormalities are associated with anti-U1-RNP antibodies and Raynaud's phenomenon in SLE patients.

Lupus. 2002,11(1):35-41.

48. Gallucci F, Russo R, Buono R, Acampora R, Madrid E, Uomo G. Indications and results of videocapillaroscopy in clinical practice. *Adv Med Sci.* 2008;53(2):1-9.

49. Ganczarzyk ML, Lee P, Armstrong SK. Nailfold capillary microscopy in polymyositis and dermatomyositis. *Arthritis Rheum.* 1988;31(1):116-9.

50. Garcia-Carrasco M, Siso A, Ramos-Casals M, Rosas J, de la Red G, Gil V et al. Raynaud's phenomenon in primary Sjögren's syndrome. Prevalence and clinical characteristics in a series of 320 patients. *J Rheumatol.* 2002;29:726-30.

51. Gasser P, Buller FR. Nailfold microcirculation in normotensive and essential hypertensive subjects, as assessed by videocapillaroscopy. *J Hypertens.* 1992;10(1):83-6.

52. Granier F, Priollet P, Housset E. Nailfold capillary microscopy in mixed connective tissue disease. Comparison with systemic sclerosis and systemic lupus erythematosus. *Arthritis Rheum.* 1986;29(2):189-95.

53. Grassi W, Felder M, Thüring-Vollenweider U,

- Bollinger A. Microvascular dynamics at the nailfold in rheumatoid arthritis. *Clin Exp Rheumatol*. 1989;7(1):47-53.
54. Grassi W, Blasetti P, Core P, Cervini C. Raynaud's phenomenon in rheumatoid arthritis. *Br J Rheumatol*. 1994; 33:139-41.
55. Grassi W, De Anglis R. Capillaroscopy: questions and answers. *Clin Reumatol*. 2007;26: 2009-16.
56. Groen H, ter Borg EJ, Postma DS, Wouda AA, van der Mark TW, Kallenberg CG. Pulmonary function in systemic lupus erythematosus is related to distinct clinical, serologic, and nailfold capillary patterns. *Am L Med*. 1992;93(6):619-27.
57. Hahn M, Klyszcz T, Jünger M, Rassner G. Local cold exposure test as therapy control in patients with Raynaud's phenomenon: comparison between laser Doppler fluxmetry and simultaneous red blood cell velocity measurements in nailfold capillaries. *Br J Dermatol*. 1995;133(5):704-9.
58. Harrison B, Herrick A, Griffiths C. Psoriasis and diffuse systemic sclerosis: a report of three patients. *Rheumatology (Oxford)*. 2000;39(2):213-5.

59. Herrick AL, Clark S. Quantifying digital vascular disease in patients with primary Raynaud's phenomenon and systemic sclerosis. *Ann Reum Dis.* 57, 1998, 70-78.
60. Herrick AL, Moore T, Hollis S, Jayson M. The influence of age on nailfold capillary dimensions in childhood. *J Rheumatol.* 2000; 27:797-800.
61. Herrick AL. Vascular imaging. *Best Pract Res Clin Rheumatol.* 2004;18(6):957-979.
62. Herrick AL. Diagnosis and management of scleroderma peripheral vascular disease. *Rheum Dis Clin North Am.* 2008;34:89-114.
63. Ho M, Belch JFF. Raynaud's Phenomenon: State of the Art 1998. *Scand J Rheumatol.* 1998; 27: 319-22.
64. Houtman PM, Kallenberg CGM, Wouda AA, The TH. Decreased nailfold capillary density in Raynaud's phenomenon: a reflection of immunologically mediated local and systemic vascular disease? *Ann Rheum Dis.* 1985;44:603-9.
65. Hu Q, Mahler F. New system for image analysis in nailfold capillaroscopy. *Microcirculation.* 1999;6(3):227-35.
66. Hudson M, Taillefer S, Steele R, Dunne J, Johnson

SR, Jones N et al. Improving the sensitivity of the American College of Rheumatology classification criteria for systemic sclerosis. *Clin Exp Rheumatol*. 2007;25(5):754-7.

67. Ingegnoli F, Zeni S, Meani L, Soldi A, Lurati A, Fantini F. Evaluation of nailfold videocapillaroscopic abnormalities in patients with systemic lupus erythematosus. *J Clin Rheumatol*. 2005;11(6):295-8.

68. Ingegnoli F, Boracchi P, Gualtierotti R. Prognostic model based on nailfold capillaroscopy for identifying Raynaud's phenomenon patients at high risk for the development of a scleroderma spectrum disorder. *Arthritis Rheum*. 2008;58(7):2174–82.

69. Kabasakal Y, Elvins DM, Ring EF, McHugh NJ. Quantitative nailfold capillaroscopy findings in a population with connective tissue disease and in normal healthy controls. *Ann Rheum Dis*. 1996;55:507-12.

70. Kahaleh B, Meyer O, Scorza R. Assessment of vascular involvement. *Clin Exp Rheumatol*. 2003;21(Suppl. 29):S9-S14.

71. Kallenberg CG, Wouda AA, Hoet MH, van Venrooij WJ. Development of connective tissue disease in patients

- presenting with Raynaud's phenomenon: a six year follow up with emphasis of predictive value of antinuclear antibodies as detecting by immunoblotting. *Ann Rheum Dis.* 1988;47:634-41.
72. Kelly RI, Pearse R, Bull RH, Leveque JL, de Rigal J, Mortimer PS. The effects of aging on the cutaneous microvasculature. *J Am Acad Dermatol.* 1995;33(5):749-56.
73. Kim H, Seo SH, Kwok SK, Ju JH, Yoon CH, Park KS et al. Nailfold capillaroscopic abnormality in systemic sclerosis: relationship with clinical manifestation. *Ann Rheum Dis.* 2006;65(Suppl.2):396.
74. Kirou KA, Crow MK. Raynaud's phenomenon. In Paget SA et al. *Manual of rheumatology and outpatient orthopedic disorders: diagnosis and therapy.* 4th ed., Philadelphia, Lippincot Williams & Willkins 2000, 82-7.
75. Koh KK, Kim SH, Lee KH, Kwon KS, Kim EJ, Baik SH et al. Does prevalence of migraine and Raynaud's phenomenon also increase in Korean patients with proven variant angina? *Int J Cardiol.* 1995;51:37-46.
76. La Montagna G, Baruffo A, Tirri R, Buono G, Valentini G. Foot involvement in systemic

- sclerosis: a longitudinal study of 100 patients. *Semin Arthritis Rheum.* 2002;31(4):248-55.
77. Lapossy E, Gasser P, Hrycaj P, Dubler B, Samborski W, Muller W. Cold-induced vasospasm in patients with fibromyalgia and chronic low back pain in comparison to healthy subjects. *Clin Rheumatol.* 1994;13(3):442-5.
78. Lee P, Leung FY, Alderdice C, Armstrong SK. Nailfold capillary microscopy in the connective tissue diseases: a semiquantitative assessment. *J Rheumatol.* 1983;10(6):930-8.
79. Le Roy EC, Medsger TAJr. Raynaud's phenomenon – a proposal for classification. *Clin Exp Rheumatol.* 1992;10:485-8.
80. Le Roy EC, Medsger TA Jr. Criteria for the classification of early systemic sclerosis. *J Rheumatol.* 2001;28:1573-6.
81. Lefford F, Edwards JCW. Nailfold capillary microscopy in connective tissue disease: a quantitative morphological analysis. *Ann Rheum Dis.* 1986;45:741-9.
82. Li L, Mac-Mary S, Marsaut D, Sainthillier JM, Nouveau S, Gharbi T et al. Age- related changes in skin topography and microcirculation. *Arch Dermatol Res.*

2006;297:412-6.

83. Li L, Mac-Mary S, Sainthillier JM, Nouveau S, de Lacharriere O, Humbert P. Age- related changes of the cutaneous microcirculation in vivo. *Gerontology*. 2006;52:142-53.

84. Ling SM, Wigley FM. Raynaud's phenomenon in older adults. Diagnostic considerations and management. *Drugs Aging*. 1999;15(3):183-95.

85. Lonzetti LS, Joyal F, Raynauld JP, Roussin A, Goulet JR, Rich E et al. Updating the American College of Rheumatology preliminary classification criteria for systemic sclerosis: addition of severe nailfold capillaroscopy abnormalities markedly increases the sensitivity for limited scleroderma. *Arthritis Rheum*. 2001;44(3):735-6.

86. Lovy M, MacCarter D, Steigerwald JC. Relationship between nailfold capillary abnormalities and organ involvement in systemic sclerosis. *Arthritis Rheum*. 1985;28(5):496-501.

87. Lukac J, Rovensky J, Tauchmannova H, Zitnan D. Effect of ketanserin on Raynaud's phenomenon in progressive systemic sclerosis: a double-blind trial.

Drugs Exp Clin Res 1985;11(9):659-63.

88. Mahler F, Nagel G, Saner H, Kneubühl F. In vivo comparison of the nailfold capillary diameter as determined by using the erythrocyte column and FITC-labelled albumin. *Int J Microcirc Clin Exp*.

1983;2(2):147-55.

89. Maricq HR, Le Roy EC, D'Angelo WA, Medsger TA Jr, Rodnan GP, Sharp GC, Wolfe JF. Diagnostic potential of in vivo capillary microscopy in scleroderma and related disorders. *Arthritis Rheum*. 1980;23(2):183-9.

90. Maricq HR, Harper FE, Khan MM, Tan EM, LeRoy EC. Microvascular abnormalities as possible predictors of disease subsets in Raynaud phenomenon and early connective tissue disease. *Clin Exp Rheumatol*.

1983;1(3):195-205.

91. Maricq HR. Comparison of quantitative and semiquantitative estimates of nailfold capillary abnormalities in scleroderma spectrum disorders.

Microvasc Res. 1986;32(2):271-6.

92. Maricq HR, Valter I. A working classification of scleroderma spectrum disorders: a proposal and the results of testing on a sample of patients. *Clin Exp*

- Rheumatol. 2004; 22(3 Suppl 33): S5-13.
93. Martino F, Agolini D, Aprigliano D, Guido F, Placanica G, Giardini O. Nailfold capillaroscopy in normal children between 0 and 16 years of age. *Minerva Pediatr.* 1997;49(5):197-201.
94. Masi AT, Medsger TA Jr, Altman RD. Preliminary criteria for the classification of systemic sclerosis (scleroderma). Subcommittee for scleroderma criteria of the American Rheumatism Association Diagnostic and Therapeutic Criteria Committee. *Arthritis Rheum.* 1980;23:581-90.
95. Matucci-Cerinic M, Steen V, Nash P, Hachulla E. The complexity of managing systemic sclerosis: screening and diagnosis. *Rheumatology (Oxford).* 2009;48(Suppl 3):iii8-13.
96. Montagna W, Carlisle K. Structural changes in aging human skin. *J Invest Dermatol.* 1979;73:47-53.
97. Morf S, Amann-Vest B, Forster A, Franzeck UK, Koppensteiner R, Uebelhart D, Sprott H. Microcirculation abnormalities in patients with fibromyalgia – measured by capillary microscopy and laser flummary. *Arthritis Res Ther.* 2005; 7:R209-R216.

98. Mulligan-Kehoe MJ, Simons M. Vascular disease in scleroderma: angiogenesis and vascular repair. *Rheum Dis Clin North Am.* 2008;34:73-9.
99. Müller-Ladner U. Raynaud's phenomenon and peripheral ischemic syndromes. 2008, 1st ed, UNI-MED Verlag AG, Bremen, pp. 36-41.
100. Nadashkevich O, Davis P, Fritzler MJ. A proposal of criteria for the classification of systemic sclerosis. *Med Sci Monit.* 2004;10(11):CR615-21.
101. Nagy Z, Czirjac L. Nailfold digital capillaroscopy in 447 patients with connective tissue disease and Raynaud's disease. *J Europ Acad Dermatol Venerol.* 2004;18:62-8
102. Nascif AK, Terreri MT, Len CA, Andrade LEC. Inflammatory myopathies in childhood: correlation between nailfold capillaroscopy findings and clinical and laboratory data. *J Pediatr.* 2006;82:40-45.
103. Naschitz JE, Rosner I, Rozenbaum M, Zuckerman E, Yeshurun D. Rheumatic syndromes: clues to occult neoplasia. *Semin Arthritis Rheum.* 1999; 29(1):43-55.
104. Nashitz JE, Rosner I, Rozenbaum M, Elias N, Yeshurun D. Cancer-associated rheumatic disorders:

- clues to occult neoplasia. *Semin Arthritis Rheum.* 1995;24(4):231-41.
105. Noon JP, Walker BR, Webb DJ, Shore AC, Holton DW, Edwards HV, Watt GC. Impaired microvascular dilatation and capillary rarefaction in young adults with a predisposition to high blood pressure. *J Clin Invest.* 1997;99:1873-9.
106. Noy-Delcourt D, Thébaut P. Periungual capillaroscopy of the toes. Criteria for norms *J Mal Vasc.* 1986;11(3):288-94.
107. Ohtsuka T. Quantitative analysis of nailfold capillary abnormalities in patients with connective tissue diseases. *Int J Dermatol.* 1999;38(10):757-64.
108. Ostojic P, Damjanov N. Different clinical features in patients with limited and diffuse cutaneous systemic sclerosis. *Clin Rheumatol.* 2006;25 :453-7.
109. Pallis M, Hopkinson N, Powell R. Nailfold capillary density as a possible indicator of pulmonary capillary loss in systemic lupus erythematosus but not in mixed connective tissue disease. *J Rheumatol.* 1991;18(10):1532-6.
110. Pavlov-Dolijanovic S, Damjanov N, Ostolic P, Susic

- G, Stojanović R, Gacić D, Grdinić A. The prognostic value of nailfold capillary changes for the development of connective tissue disease in children and adolescents with primary Raynaud's phenomenon: a follow-up study of 250 patients. *Pediatric dermatol.* 2006. 23(5):437-42.
111. Paw P, Dharan SM, Sackier JM. Digital ischemia and occult malignancy. *Int J Colorectal Dis.* 1996;11:196-7.
112. Prasad A, Dunnill GS, Mortimer PS at Mac Gregor GA. Capillary rarefaction in the forearm skin in essential hypertension. *J Hypertens.* 1995;13(2):265-8.
113. Redisch W. Capillaroscopic observations in rheumatic diseases. *Ann Reum Dis.* 1970; 29:244-53.
114. Reeves WH, Fisher DE, Wisniewolski R, Gottlieb AB, Chiorazzi N. Psoriasis and Raynaud's phenomenon associated with autoantibodies to U1 and U2 small nuclear ribonucleoproteins. *N Engl J Med.* 1986;315(2):105-11.
115. Riccieri V, Spadaro A, Ceccarelli F, Scrivio R, Germano V, Valesini G. Nailfold capillaroscopy changes in systemic lupus erythematosus: correlation with disease activity and autoantibody profile. *Lupus.* 2005;14:521-5.

116. Salli L, Raimondi F, Pappalardo A. Periungual capillaroscopy in psoriatic arthritis. *Clin Term.* 1999;150(6):409-12.
117. Saraux A, Allain J, Guedes C, Baron D, Youinou P, Le Goff P. Raynaud's phenomenon in rheumatoid arthritis. *Br J Rheumatol.* 1996;35(8):752-4.
118. Sato LT, Kayser C, Andrade LE. Nailfold capillaroscopy abnormalities correlate with cutaneous and visceral involvement in systemic sclerosis patients. *Acta Reumatol Port.* 2009; 34(2A):219-27.
119. Schmidt JA, Caspary L, von Bierbrauer A, Ehrly AM, Jünger M, Jung F, Lawall H. Standardisierung der Nagelfalz-Kapillarmikroskopie in der Routinediagnostik. *Vasa.* 1997;25:5-10.
120. Sebastiani M, Manfredi A, Colaci M, D'amico R, Malagoli V, Giuggioli D, Ferri C. Capillaroscopic skin ulcer risk index: a new prognostic tool for digital skin ulcer development in systemic sclerosis patients. *Arthritis Rheum.* 2009;15;61(5):688-94.
121. Secchi ME, Sulli A, Pizzorni C, Cutolo M. Endothelin-1 in systemic sclerosis. *Reumatismo.* 2007;59(2):129-34.

122. Seibold JR, Steen VD. Systemic sclerosis. In: Klippel JH, Dieppe PA. Rheumatology. London: Mosby; 1994: 6.8.- 6.11.
123. Sherber NS, Wigley FM, Scher RK. Autoimmune disorders: nail signs and therapeutic approaches. *Dermatol Ther.* 2007;20(1):17-30.
124. Scheja A, Akesson A, Niewierowicz I, Wallin L, Wildt M, Wollheim FA. Computer based quantitative analysis of capillary abnormalities in systemic sclerosis and its relation to plasma concentration of von Willebrand factor. *Ann Rheum Dis.* 1996;55:52-6.
125. Schlez A., Hafner HN, Kittel M, Braun S, Diehm C, Jünger M. Systemic scleroderma patients have improved skin perfusion after the transdermal application of PGE1 ethyl ester. *Vasa.* 2003;32(2):83-6.
126. Shore AC. Capillaroscopy and measurement of capillary pressure. *Br J Clin Pharmacol.* 2000;50(6):501-13.
127. Silver RM, Thomas A, Medsger TA Jr, Bolster MB. Systemic sclerosis and scleroderma variants:clinical aspects. In: Koopman W.J. Arthritis and allied conditions. 15th ed. Lippincot Williams&Wilkins, 2005,

pp. 1633-80.

128. Smolen JS, Steiner G. Mixed connective tissue disease: to be or not to be? *Arthritis Rheum.*

1998;41(5):768–77.

129. Smyth AE, Hughes AE, Bruce IN, Bell AL. A case control study of candidate vasoactive mediator genes in primary Raynaud's phenomenon. *Rheumatology (Oxford)*. 1999; 38:1094-8.

130. Sontheimer RD. A portable digital microphotography unit for rapid documentation of periungual nailfold capillary changes in autoimmune connective tissue diseases. *J Rheumatol* 2004; 31:539-544.

131. Spengler MI, Svetaz MJ, Leroux MB, Leiva ML, Bottai HM. Association between capillaroscopy, haemorheological variables and plasma proteins in patients bearing Raynaud's phenomenon. *Clin Hemorheol Microcirc.* 2004;30(1):17-24.

132. Steven AO. Raynaud's phenomenon. In: Sterling JB. *Secrets of rheumatology*. Moscow: Binom; 2001, pp. 614-9.

133. Sulli A, Pizzorni C, Cutolo M. Nailfold

videocapillaroscopy abnormalities in patients with antiphospholipid antibodies. *J Rheumatol.*

2000;27(6):1574-6.

134. Sulli A, Secchi ME, Pizzorni C, Cutolo M. Scoring of nailfold microvascular changes during capillaroscopic analysis in systemic sclerosis patients. *Ann Rheum Dis.*

2008;67(6):885-7.

135. Susol E, MacGregor AJ, Barrett JH, Wilson H, Black C, Welsh K et al. A two- stage, genome-wide screen for susceptibility loci in primary Raynaud's phenomenon. *Arthritis Rheum.* 2000;43(7):1641-6.

136. Tan EM, Cohen AS, Fries JF, Masi AT, McShane DJ, Rothfield NF et al. The 1982 revised criteria for the classification of systemic lupus erythematosus. *Arthritis Rheum.* 1982; 25:1271-7.

137. Targoff IN. Humoral immunity in polymyositis/ dermatomyositis. *J Invest Dermatol.* 193;100 (1):116S – 23S.

138. Taylor W., Gladman D, Helliwell P, Marchesoni A, Mease P, Mielants H. Classification criteria for psoriatic arthritis. Development of new criteria from a large international study. *Arthritis Rheum.* 2006; 54(8): 2665–

73.

139. Tektonidou M, Kaskani E, Skopouli FN, Moutsopoulos HM. Microvascular abnormalities in Sjögren's syndrome: nailfold capillaroscopy. *Rheumatology (Oxford)*. 1999; 38: 826-30.

140. Terreri MTRA, Andrade LAC, Puccinelli ML, Hilario MOE, Goldenberg J. Nailfold capillaroscopy: normal findings in children and adolescents. *Semin Arthritis Rheum*. 1999;29:36-42.

141. Ushiyama O, Ushiyama K, Yamada T, Koarada S, Tada Y, Suzuki N et al. Retinal findings in systemic sclerosis: a comparison with nailfold capillaroscopic patterns. *Ann Rheum Dis*. 2003;62:204-7.

142. Vaz JLP, Dancour AA, Bottino DA, Bouskela E. Nailfold videocapillaroscopy in primary antiphospholipid syndrome. *Rheumatology (Oxford)*; 2004;43:1025-7.

143. Walker JG. The development of systemic sclerosis classification criteria. *Clin Rheumatol*. 2007;26:1401-9.

144. Weinbacher M, Martina B, Gasser P, Kohler M, Bart T. Nail fold capillaroscopy and echocardiography in mild to moderate hypertension treated with cilazapril plus hydrochlorothiazide: first results. *J Cardiovasc Pharmacol*.

1994;24(Suppl. 3):S83-5.

145. Wolfe F, Cathey MA, Kleinheksel SM. Fibrositis (Fibromyalgia) in rheumatoid arthritis. *J Rheumatol.* 1984;11(6):814-8.

146. Wolfe F, Smythe HA, Yunus MB, Bennett RM, Bombardier C, Goldenberg DL et al. The American College of rheumatology 1990 criteria for the classification of fibromyalgia. Report of the Multicenter Criteria Committee. *Arthritis Rheum.* 1990;33(2):160-72.

147. Wright CI, Kroner CI, Draijer R. Non-invasive methods and stimuli for evaluation the skin's microcirculation. *J Pharmacol Toxicol Med.* 2006;54:1-25.

148. Ziegler S, Brunner E, Eigenbauer E, Minar E. Long-term outcome of primary Raynaud's phenomenon and its conversion to connective tissue disease: a 12-year prospective patient analysis. *Scand J Rheumatol.* 2003; 32:343-7.

ACKNOWLEDGEMENTS

It was a unique opportunity to come to Germany to the Justus Liebig University, Gießen, Department for Internal Medicine and Rheumatology, Department for Rheumatology and Clinical Immunology, Kerckhoff Clinic, Bad Nauheim and to be able to perform the research and do the work for this dissertation. I am grateful to the chair of the Department Prof. Dr Ulf Müller-Ladner for inviting me and for providing the logistic and scientific support for my work. I highly appreciate and I am thankful to him for the opportunities that he has given to me, for his guidance and constant encouragement. And most importantly I want to thank him for his confidence in me and for the hope, that he has given to me to continue working irrespective of the impediments, that sometime seem to be insurmountable. Because this gave me oppottunities, which I otherwise would not have had and without them this thesis would not have been possible. His enthusiasm and devotion to Rheumatology and science will be always remembered.

My sincere thanks are also due to the members of his team for their help and cooperation. I would like to

take this opportunity to thank especially to Dr. Walter Hermann (who is the second investigator, who has analyzed the capillaroscopic images qualitatively), Prof. Robert Dinsler, Prof. Uwe Lange and Dr. Gerald Stapfer.

My work in Germany was supported by a research stipend of the EULAR. I would also like to thank EULAR for the opportunity, that they have given to me.

I would like to thank to my parents – Nikola Lambov und Dona Lambova for their support in the course of my scientific work, development and preparation of this work.

PUBLICATIONS, ORIGINATING FROM THE DISSERTATION

1. Lambova S., Müller-Ladner U. The role of capillaroscopy in differentiation of primary and secondary Raynaud's phenomenon in rheumatic diseases: a review of the literature and two case reports.

Rheumatol Int. 2009; 29(11):1263-71.

2. Lambova S., Müller-Ladner U. The specificity of capillaroscopic pattern in connective autoimmune diseases - a comparison with microvascular changes in diseases of social importance: arterial hypertension and diabetes mellitus. Mod Rheumatol 2009; 19(6):600-5.

3. Lambova S., Müller-Ladner U. Capillaroscopic pattern in systemic sclerosis – an association with processes of angiogenesis and vasculogenesis. Microvasc Res.

2010;80(3):534-9.

4. Lambova S., Hermann W., Müller-Ladner U. Capillaroscopic pattern of the toes - does it “tell” more than those of fingers? J Clin Rheumatol. 2011;17(6):311-4.

5. Lambova S., Müller-Ladner U. Capillaroscopic pattern

in paraneoplastic Raynaud's phenomenon. *Rheumatol Int.* 2011. (in the press).

6. Lambova S, Hermann W, Müller-Ladner U.

Comparison of qualitative and quantitative analysis of capillaroscopic findings in patients with rheumatic diseases. *Rheumatology Int* 2011 (in the press).

7. Lambova S, Müller-Ladner U. Capillaroscopic findings in systemic sclerosis - are they associated with disease duration and presence of digital ulcers? *Discov Med* 2011; 12(66):413-8.

8. Lambova S., Kuzmanova St. Raynaud's phenomenon in common rheumatic diseases. *Folia medica – Plovdiv, Folia medica – Plovdiv, Bulgaria, 2006; 3&4:22-8.*

9. Lambova S. The role of capillaroscopy in rheumatology. *Rheumatology - Sofia, Bulgaria, 2008. 1-2:17-27.*

10. Lambova S., Kuzmanova St. The pathogenesis of Raynaud's phenomenon. *Rheumatology – Sofia, Bulgaria, 2005; 3: 62-65.*

SCIENTIFIC ABSTRACTS IN CONFERENCES

1. Lambova S, Müller-Ladner U. The role of capillaroscopy in rheumatology – results from EULAR project 2009. Rheumatology Sofia, 2009 – congress edition;3:13 – an oral presentation.
2. Lambova S, Müller-Ladner U. Capillaroscopic pattern at the toes of systemic sclerosis patients – does it “tell” more than those of fingers? Rheumatology Sofia, 2009 – congress edition;3:25 – an oral presentation.
3. Lambova S, Müller-Ladner U. Capillaroscopic pattern in primary fibromyalgia.
Rheumatology Sofia, 2009 – congress edition;3:26.
4. Lambova S, Müller-Ladner U. Capillaroscopic pattern in inflammatory arthritis.
Rheumatology Sofia, 2009 – congress edition;3:25.
5. Lambova S, Hermann W., Müller-Ladner U. Our experience with capillaroscopic pattern in paraneoplastic Raynaud’s phenomenon – report of three cases.
Rheumatology Sofia, 2009 – congress edition;3:26.
6. Lambova S, Müller-Ladner U. Capillaroscopic pattern and immunologic profile in patients with systemic lupus erythematosus. Rheumatology Sofia, 2009 – congress

edition;3:12.

7. Lambova S, Müller-Ladner U, Hermann W.

Capillaroscopy of the toes in patients with systemic sclerosis - is it worth to perform it? National German congress of Rheumatology, 2009; Number: OB.23.

Poster. Z Rheumatol. 2009;68(Suppl 1):1-104.

8. Lambova S, Müller-Ladner U, Hermann W.

Capillaroscopic pattern in patients with rheumatoid arthritis. National German congress of Rheumatology, 2009; Number: OB.03. Poster. Z Rheumatol.

2009;68(Suppl 1):1-104.

9. Lambova S, Mueller-Ladner U., Hermann W.

Comparison of qualitative and semiquantitative analysis of capillaroscopic findings in patients with rheumatic diseases. National German congress in Rheumatology.

2009; Number: OB.05. Poster. Z Rheumatol 2009; 68 (Suppl 1):1-104.

10. Lambova S, Müller-Ladner U. The role of capillaroscopy in rheumatology – results from EULAR project 2009. EULAR congress 2010, 16-19 Jun, Rome, Italy, Ann Rheum Dis 2010; 69 (Suppl 3):713.

11. Lambova S, Müller-Ladner U. Capillaroscopic

pattern at the toes of systemic sclerosis patients – does it “tell” more than those of fingers? EULAR congress 2010, 16-19 Jun, Rome, Italy, *Ann Rheum Dis* 2010; 69 (Suppl 3):692.

12. Lambova S, Müller-Ladner U. Capillaroscopic pattern in primary fibromyalgia and in primary Raynaud’s phenomenon. EULAR congress 2010, 16-19 Jun, Rome, Italy, *Ann Rheum Dis*. 2010;69 (Suppl 3): 451.

13. Lambova S, Hermann W, Müller-Ladner U. Comparison of capillaroscopic findings at fingers and toes in systemic sclerosis. 1st Systemic Sclerosis World Congress, 11-13 Feb 2010, Florence, Italy; *Clin Exp Rheumatol* 2010;28(2) (Suppl 58): S-172.

14. Lambova S, Müller-Ladner U. Association between capillaroscopic changes in systemic sclerosis patients and presence of digital ulcers. 1st Systemic Sclerosis World Congress, 11-13 Feb 2010, Florence, Italy; *Clin Exp Rheumatol* 2010;28(2) (Suppl 58): S-172.

15. Lambova S, Hermann W, Müller-Ladner U. Comparison of qualitative and quantitative analysis of capillaroscopic findings in patients with rheumatic

diseases. *Ann Rheum dis* 2011; 70(3):553.

16. Lambova S, Müller-Ladner U. The place of nail fold capillaroscopy in the diagnostic algorithm of inflammatory arthritis. *Ann Rheum dis* 2011; 70(3):552.

17. Lambova S, Müller-Ladner U. An association of capillaroscopic pattern with presence of digital ulcers in systemic sclerosis. *Rheumatology Sofia – congress edition, 2011;3:21* – an oral presentation.

18. Lambova S, Müller-Ladner U. The specificity of capillaroscopic changes in rheumatic disease – a comparison with the microvascular changes in the diseases with social importance – arterial hypertension and diabetes mellitus. *Rheumatology Sofia – congress edition, 2011;3:39* – a poster.

19. Lambova S. The role of capillaroscopy in rheumatology. *National Congress of Rheumatology, Sunny beach, 25-28 Sep 2008, Bulgarian Union of Rheumatology – congress edition 2008:pp. 49-50.*

20. Lambova S, Nikolova JG. The role of capillaroscopy for the early diagnosis of systemic sclerosis. *National Congress of Rheumatology, Sunny beach, Bulgaria, 25-28 Sep 2008, Bulgarian Union of Rheumatology –*

congress edition 2008:pp. 53-54.

53-4.

21. Lambova S., Kuzmanova St. The pathogenesis of Raynaud's phenomenon. VIIIth National Congress in Rheumatology with international participation; 4-5Nov, 2005, Rheumatology – Sofia, 2005;3:27.

22. Lambova S., Kuzmanova St. Therapy with Iloprost in patients with severe Raynaud's phenomenon secondary to scleroderma. Annual European Congress in Rheumatology, Amsterdam, 21-24 June, 2006; Ann Rheum Dis 2006;65(Suppl 11):396-7.

Erklärung

Ich erkläre: Ich habe die vorgelegte Dissertation selbständig, ohne unerlaubte fremde Hilfe und nur mit den Hilfen angefertigt, die ich in der Dissertation angegeben habe. Alle Textstellen, die wörtlich oder sinngemäß aus veröffentlichten oder nicht veröffentlichten Schriften entnommen sind, und alle Angaben, die auf mündlichen Auskünften beruhen, sind als solche kenntlich gemacht. Bei den von mir durchgeführten und in der Dissertation erwähnten Untersuchungen habe ich die Grundsätze guter wissenschaftlicher Praxis, wie sie in der “Satzung der Justus-Liebig-Universität Gießen zur Sicherung guter wissenschaftlicher Praxis” niedergelegt sind, eingehalten.

**Der Lebenslauf wurde aus der elektronischen
Version der Arbeit entfernt.**

**The curriculum vitae was removed from the
electronic version of the paper.**